



DIFFERENT SUTURE CONFIGURATIONS FOR TRANSTIBIAL PULLOUT REPAIR FOR MEDIAL MENISCUS ROOT TEARS YIELD IMPROVED MID-TERM CLINICAL OUTCOMES: A SYSTEMATIC REVIEW

G.R. JACKSON¹, J.S. LEE¹, S. ASIF¹, D. SACHDEV¹, E.S. MAMERI^{1,2,3},
D.J. KAPLAN¹, Z.A. KHAN¹, H. JAWANDA¹, A.K. BATRA¹, O.A. OBIOHA¹,
D.M. KNAPIK⁴, F. FAMILIARI⁵, R.F. LAPRADE⁶, J. CHAHLA¹

• • •

¹Department of Orthopaedic Surgery, Rush University Medical Center, Chicago, IL, USA

²Instituto Brasil de Tecnologia da Saúde, Rio de Janeiro, Brazil

³Department of Orthopedics and Traumatology, Federal University of São Paulo (EPM-UNIFESP), São Paulo, Brazil

⁴Department of Orthopaedic Surgery, Washington University and Barnes-Jewish Orthopedic Center, Chesterfield, MO, USA

⁵Department of Orthopaedic and Trauma Surgery, Magna Graecia University, Catanzaro, Italy

⁶Twin Cities Orthopedics, Edina, MN, USA

CORRESPONDING AUTHOR

Garrett R. Jackson, MD; e-mail: grjackson.md@gmail.com

ABSTRACT – Objective: This work aimed to compare the clinical outcomes following medial meniscus posterior root repairs using different suture configuration repair techniques.

Materials and Methods: A comprehensive literature search was conducted by querying EMBASE, PubMed, and Scopus computerized databases from databases inception through November 2022, in accordance with the 2020 Preferred Reporting Items for Systematic Review and Meta-Analysis (PRISMA) guidelines. Level of evidence I, II, or III studies that reported clinical outcomes undergoing transtibial pullout repair for MMPR tears were included (simple stitch, all-inside-dependent modified Mason-Allen, modified reverse Mason-Allen, and cinch-loop). Methodological quality assessment of the included studies was performed using the Newcastle-Ottawa Scale and the National Institute of Health Quality Assessment.

Results: Twelve studies, including 495 patients, met the inclusion/exclusion criteria. The reported mean post-operative Lysholm score among simple stitch patients ranged from 73.4 to 92.5, vs. 84.7 to 85.9 in all-inside-dependent modified Mason-Allen patients, 71.5-87.6 in modified reverse Mason-Allen patients, and 81.8-88.8 in cinch-loop patients. The reported mean improvement in IKDC score among simple stitch patients ranged between 59.2 and 91.8, vs. 63.2 and 65.3 in all-inside-dependent modified Mason-Allen patients, 55.6-78.4 in modified reverse Mason-Allen patients, and 76.7 in cinch-loop patients.

Conclusions: Patients undergoing simple stitch, all-inside-dependent modified Mason-Allen, modified reverse Mason-Allen, and cinch-loop transtibial pullout repair for MMPR tears all reported improvement in Lysholm and IKDC scores. Future prospective studies evaluating postoperative outcomes in patients undergoing MMPR repair based on suture configuration repair techniques are warranted to better determine optimal transtibial pullout repair treatment.

KEYWORDS: Root repair, Knee, Meniscus, Transtibial pullout repair.



This work is licensed under a [Creative Commons Attribution-NonCommercial-ShareAlike 4.0 International License](https://creativecommons.org/licenses/by-nc-sa/4.0/)

INTRODUCTION

Tears of the medial meniscus posterior root (MMPR) compromise the stability of the meniscus, leading to meniscus extrusion, loss of hoop stress distribution, and increased contact pressures within the tibiofemoral articulation, resulting in the development of premature osteoarthritis¹. Biomechanical studies²⁻⁴ have demonstrated that untreated MMPR tears result in a functional state comparable to meniscal deficiency, with repairs effectively normalizing joints. Krych et al^{5,6} observed that nonoperative treatment of MMPR tears led to rapid joint degradation based on Kellgren-Lawrence grade, increasing the rate of total knee arthroplasty (TKA) conversion, while partial meniscectomy did not confer any advantages over nonoperative management as a palliative treatment option. Patients without a repaired MMPR tear have also been reported⁷ to experience clinical failure in 87% of cases, resulting in a 31% requiring TKA conversion rate within the first five years following surgery. Accordingly, MMPR repair is generally recommended to appropriately indicated patients to improve function and slow arthritic progression⁸.

Established techniques for MMPR repairs are grouped into two main categories: all-inside suture anchor repair vs. transtibial pull-out repair⁹⁻¹¹. Both techniques have reported¹² clinical benefits without significant differences in load to failure; however, the use of an all-inside suture anchor repair is technically demanding relative to tibial tunnel drilling¹³. Among transtibial pullout repair techniques, a variety of suture configurations have also been reported¹³; however, there exists a paucity of research comparing clinical outcomes between suture techniques.

Given the critical role the medial meniscal root plays in joint biomechanics, understanding the benefits of each suture method may help better inform surgeons which technique yields improved outcomes and decreased failure rates. The purpose of this study was to compare the clinical outcomes following medial meniscus posterior root repairs using different suture configuration repair techniques. The authors hypothesized that there would be no difference in clinical outcomes between suture techniques.

MATERIALS AND METHODS

Search Strategy and Eligibility Criteria

A literature review was performed in accordance with the 2020 Preferred Reporting Items for Systematic Review and Meta-Analysis (PRISMA) guidelines¹⁴. Two independent authors (J.L., S.A.) performed a comprehensive literature search using EMBASE, PubMed, and Scopus computerized databases to identify studies reporting clinical outcomes for patients undergoing repair of MMPR tears using a transtibial pull-out repair technique. Studies published from inception to November 2022 were searched. The systematic search criteria included the following search terms combined with Boolean operators: “medial meniscus”, “root”, “posterior root”, “repair”, “outcomes”, and “trans-tibial”. Inclusion criteria consisted of Level I to III clinical studies written in English or with English translation reporting clinical outcomes following MMPR repair using transtibial pull-out repair using one of the following suture configurations: simple stitch, all-inside-dependent modified Mason-Allen, modified reverse Mason-Allen, and cinch-loop (Figure 1). A simple stitch configuration includes passing two sutures through the root⁴ (Figure 2). An all-inside-dependent modified Mason-Allen technique includes placing one horizontal mattress suture and then a 2nd suture across the first, with the first acting as a rip-stop¹⁵. A modified reverse Mason-Allen is similar, except the horizontal mattress is placed from inferior to superior so that the suture limbs exit from the superior aspect of the meniscus leaflet rather than the inferior¹⁶. A cinch-loop is a luggage tag stitch, where one limb of the suture is pulled through a pre-made loop on the other limb, forming the cinch¹⁷. Nonclinical studies (i.e., cadaveric, animal, or biomechanical), review articles, abstracts, editorials, studies of level IV or V evidence, commentaries and studies not reporting on outcomes, suture configuration, studies not separating outcomes based on suture technique with overlapping cohorts were excluded.

Data Extraction and Statistical Analysis

Data from the selected studies was entered into a spreadsheet using Microsoft Excel version 16.63 (Microsoft Corp, Redmond, WA, USA). Categories for data collection included: article information (journal, year, level of evidence), patient demographics [patient age, sex, body mass index (BMI)], and time from injury to surgery], surgical technique [number of sutures, number of tibial tunnels, size of the tibial tunnel(s) and tibial fixation method], mean follow up time, and patient-reported outcomes scores [Lysholm,

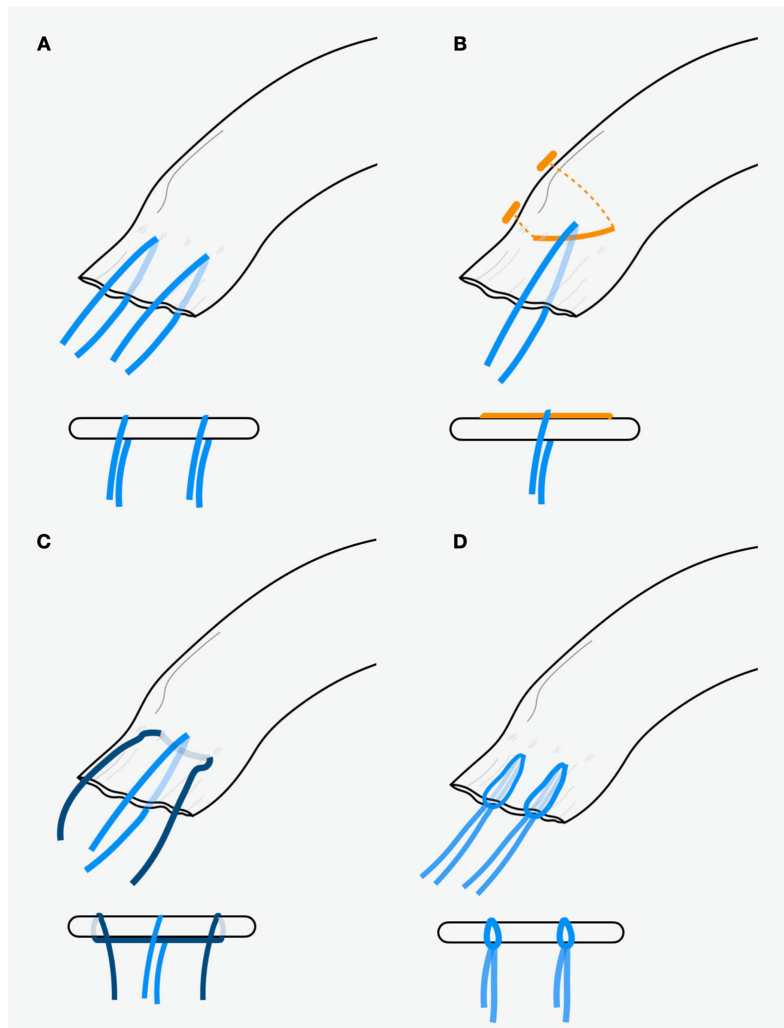


Figure 1. Medial meniscus posterior root repair using a transtibial pull-out repair (A) with two simple stitches all-inside modified Mason-Allen technique (B), modified reverse Mason-Allen technique (C), and cinch-loop technique (D).

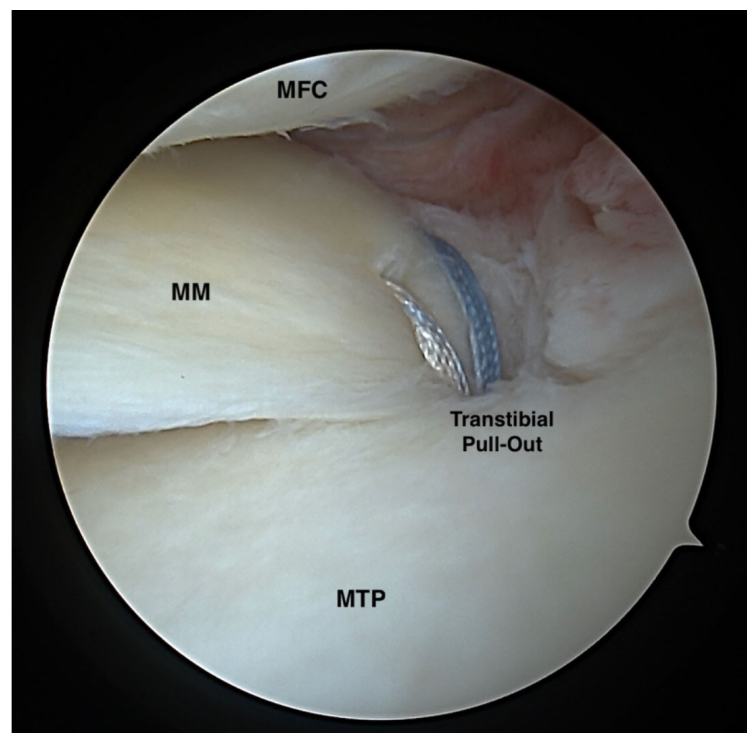


Figure 2. Medial meniscus posterior root repair in a left knee using a transtibial pull-out repair with two simple stitches. MFC, medial femoral condyle; MM, medial meniscus; MTP, medial tibial plateau

International Knee Documentation Committee (IKDC)]. Forest plots were created using Review Manager 5 (The Nordic Cochrane Center, Copenhagen, Denmark) to illustrate preoperative and postoperative Lysholm and IKDC scores for each technique. Heterogeneity was measured using the I^2 statistic. I^2 can be interpreted as follows: 0% to 25%: Low heterogeneity; 26% to 50%: Moderate heterogeneity; 51% to 75%: Substantial heterogeneity; 76% to 100%: Considerable heterogeneity.

Risk of Bias Assessment

To evaluate the risk of bias in the included studies, two investigators (J.L., D.S.) independently performed a quality assessment using the Newcastle-Ottawa Scale (NOS) score and the National Institute of Health (NIH) Quality Assessment score. Full details on the bias assessment can be found in [Appendix 1](#) and [Appendix 2](#).

RESULTS

Demographics

The initial search yielded a total of 1,645 articles, of which 672 duplicates were removed. Following title and abstract screening, 102 full-text articles were evaluated (Figure 3). Following the full-text screening, 12 studies^{9,16-26} (n=19 cohorts), consisting of 495 patients, were identified as meeting inclusion/exclusion criteria. The included studies were published between 2011 and 2022. The mean NOS score was 8.08 (range: 7-9), and the mean NIH Quality Assessment score was 11.75 (range: 10-13). Eight studies^{9,18-24} (n=242 patients; mean age range: 52.9-65.4 years) reported using a simple stitch technique, 3 studies^{20,21,26} (n=97

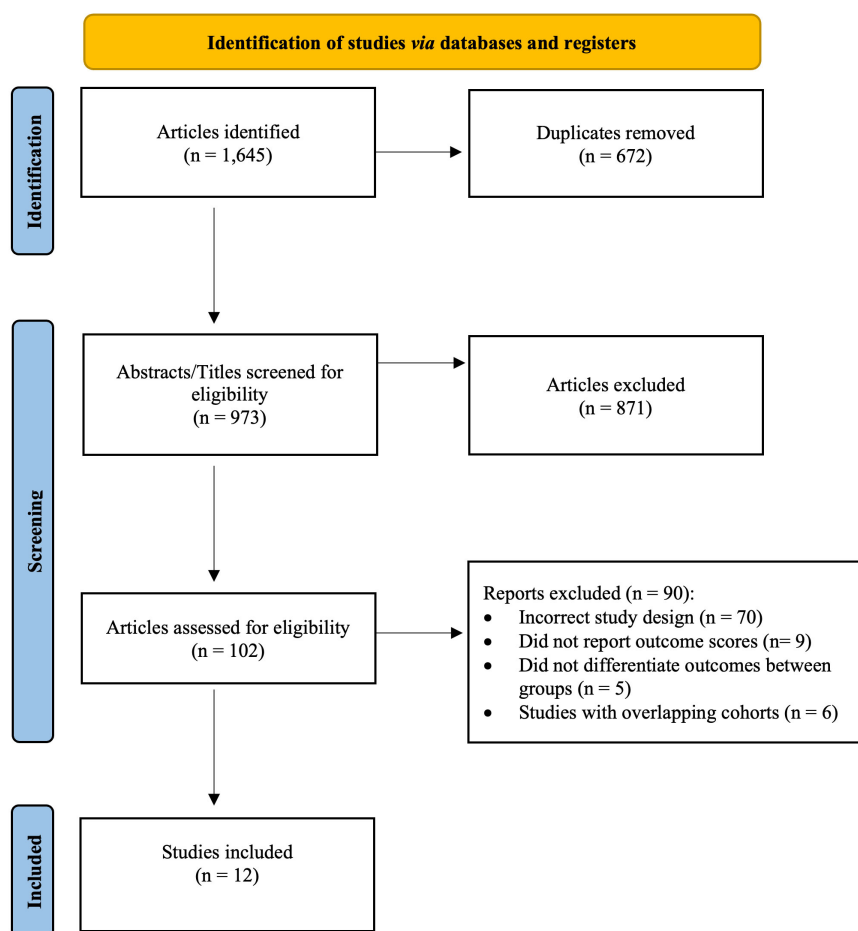


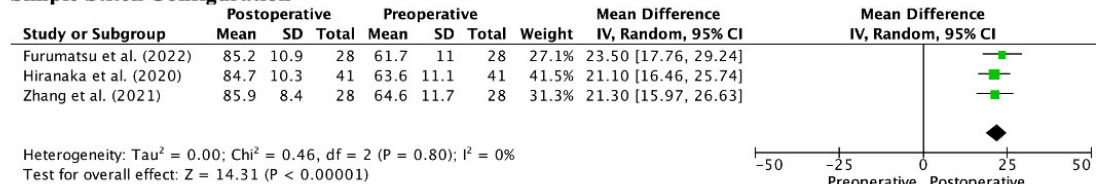
Figure 3. Preferred Reporting Items for Systematic Review and Meta-Analysis (PRISMA) diagram demonstrating study selection process.

patients; mean age range, 63.0-63.9 years) reported on all-inside-dependent modified Mason-Allen, 2 studies^{16,23} (n=88 patients; mean age range: 52.7-56.0 years) reported on modified reverse Mason-Allen, and 3 studies^{17,24,25} (n=68 patients; mean age range: 47.2-61.5 years) reported on cinch-loop technique. The mean duration of follow-up for simple stitch ranged from 12 to 125.9 months, all-inside-dependent modified Mason-Allen ranged from 24 to 16.6 months, modified reverse Mason-Allen ranged from 24 to 24.1 months, and cinch-loop ranged from 12 to 44.6 months (Appendix 3).

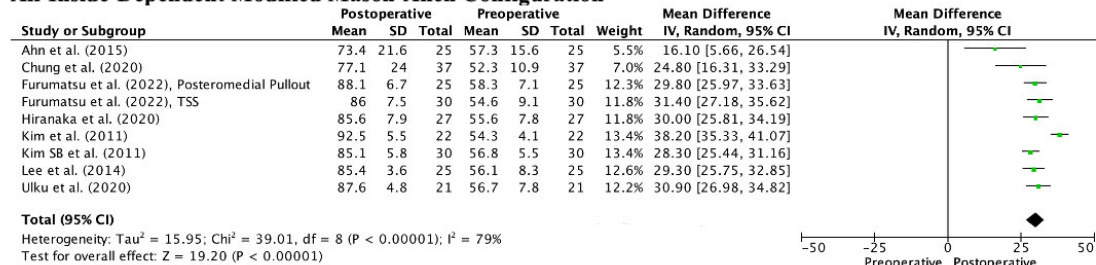
Clinical Outcome Scores

All twelve studies (n=495 patients) reported preoperative and postoperative Lysholm scores. The reported mean postoperative Lysholm score among simple stitch patients ranged from 73.4 to 92.5 points, vs. 84.7-85.9 points in all-inside-dependent modified Mason-Allen patients, 71.5-85.9 points in modified reverse Mason-Allen patients, and 81.8-88.8 points in cinch-loop patients (Figure 4). Ten studies^{9,16-23,26}

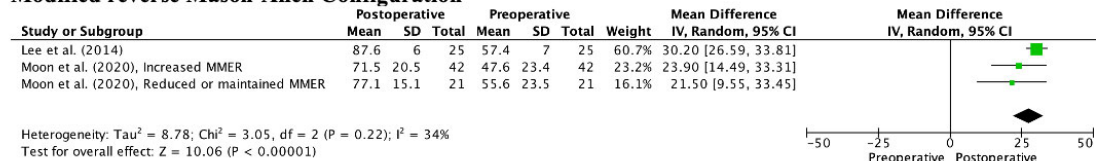
Simple Stitch Configuration



All-Inside-Dependent Modified Mason-Allen Configuration



Modified reverse Mason-Allen Configuration



Cinch-loop Stitch Configuration

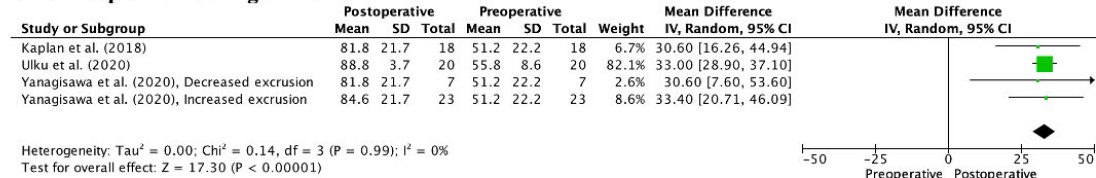


Figure 4. Forest plot illustrating Lysholm scores for each technique.

(n=424 patients) consisting of 221 simple stitch patients, 97 all-inside-dependent modified Mason-Allen patients, 88 modified reverse Mason-Allen patients, and 18 cinch-loop patients reported preoperative and postoperative International Knee Documentation Committee (IKDC) scores (Figure 5). The reported mean postoperative IKDC score among simple stitch patients ranged from 59.2 to 91.8 points, vs. 63.2-65.3 points in all-inside-Dependent modified Mason-Allen patients, 55.6-78.4 points in Modified reverse Mason-Allen patients, and 76.7 points in cinch-loop patients (Appendix 4).

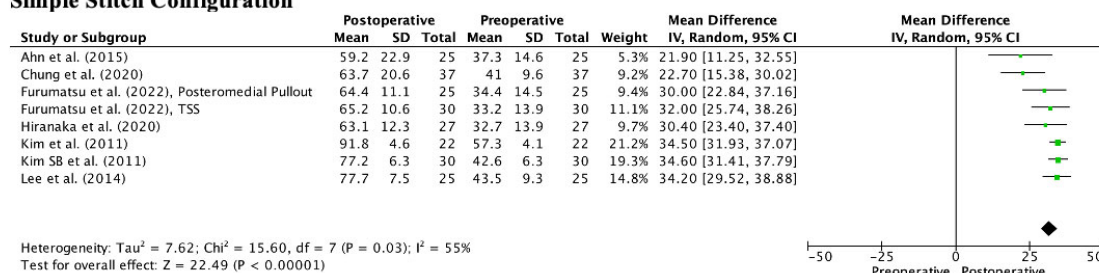
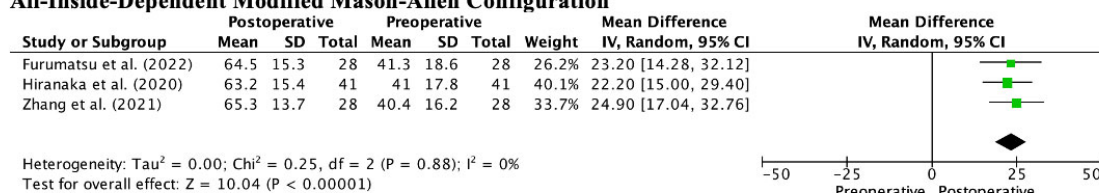
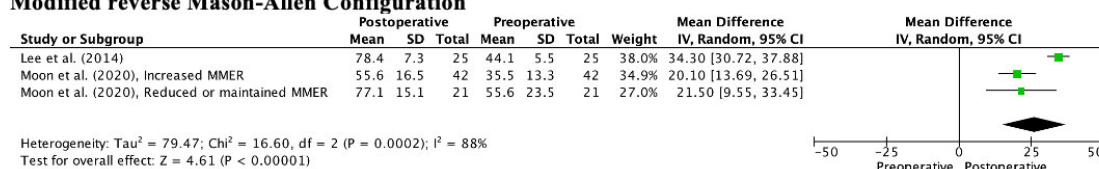
Simple Stitch Configuration**All-Inside-Dependent Modified Mason-Allen Configuration****Modified reverse Mason-Allen Configuration**

Figure 5. Forest plot illustrating the International Knee Documentation Committee (IKDC) scores for each technique.

DISCUSSION

The most important finding from this systematic review report is that among the four suture techniques evaluating TPR, clinical improvement was observed in both Lysholm and IKDC scores at a minimum of 12-month follow-up.

While all four techniques resulted in patient-reported outcome (PRO) score improvement at follow-up, simple stitch, and cinch loop techniques were reported to yield higher mean Lysholm and IKDC scores at the final follow-up when compared to Mason-Allen techniques. Simple stitches have proven effective in root repair studies^{22,27} in terms of postoperative PRO scores and decreased joint space narrowing compared to nonoperative treatment or partial meniscectomy. As tissue available for suture passage is comparatively limited in the meniscal root, it is possible that the associated tissue trauma using either Mason-Allen configuration (must pass suture 3 times vs. only 2 times for simple stitch and loop cinch) may have a detrimental effect without yielding a clinical advantage.

Numerous studies^{5,6,27-29} report rapid arthritis progression in MMPR tears patients treated nonoperatively^{5,6} and following meniscectomy²⁷⁻²⁹, along with delayed repair. While successful root repair has been shown in the literature to slow joint degeneration, arthritic progression is not eliminated due to multiple factors, including partial root healing and incomplete restoration of native joint biomechanics (evidenced by residual extrusion). Suture configuration, therefore, may not be the primary factor dictating outcomes, but rather the lack of restored anatomy. Krych et al¹³ demonstrated that extrusion might be due to the presence of persistent meniscotibial ligament tears (as part of a cascade leading to MMPR tears), which implies that additional fixation is required beyond the root to restore native kinematics. Using a centralization stitch may not only decrease extrusion but could synergistically restore contact mechanics of the knee³⁰. This improved repair construct may help to improve the ability of the meniscus to absorb and transmit load better, further slowing KL progression, regardless of the suture configuration used for the root repair³¹.

Limitations

The results of this study must be interpreted through the context of its limitations. First, due to the limited number of available prospective investigations, reported outcomes were derived solely from level III studies. As a result, statistical outcomes were reported as descriptive summaries of the means, limiting the ability to make meaningful statistical comparisons between transtibial pullout repair techniques. Second, due to the small sample size, a minimum follow-up was not required for the eligibility criteria. The mean follow-up of included studies ranged from 12 to 84.8 months, leading to a substantial amount of variation between patient-reported outcomes, complication rates, incomplete healing, and conversion rates to TKA. Furthermore, since the rates of transtibial pullout repair failure increase with time, the short duration of follow-up in some studies may have impacted the current findings. Third, the lack of comparable systematic reviews comparing the outcomes of different transtibial pullout repair techniques, makes it difficult to assess the validity of the current study's findings. Additionally, as most studies aggregately reported patient outcomes, determining risk factors for transtibial pullout repair failure by technique was not able to be reliably performed. Lastly, our search strategy and eligibility criteria may have unintentionally excluded studies with eligible cohorts.

CONCLUSIONS

Patients undergoing simple stitch, all-inside-dependent modified Mason-Allen, modified reverse Mason-Allen, and cinch-loop transtibial pullout repair for MMPR tears all reported mean improvement in Lysholm and IKDC scores. Future prospective studies evaluating postoperative outcomes in patients undergoing MMPR repair based on suture technique are warranted to better determine optimal transtibial pullout repair treatment.

CONFLICT OF INTEREST:

The authors declare that they have no conflict of interest.

FUNDING:

Open access funding provided by Università degli Studi Magna Graecia di Catanzaro within the CRUI-CARE Agreement.

AVAILABILITY OF DATA AND MATERIALS:

All data generated or analyzed during this study are included in this manuscript.

INFORMED CONSENT:

Not applicable.

ETHICS APPROVAL:

Not applicable.

AUTHORS' CONTRIBUTIONS:

Each author fulfills each of the authorship requirements. All authors have contributed equally.

REFERENCES

1. Krych AJ, Hevesi M, Leland DP, Stuart MJ. Meniscal Root Injuries. *J Am Acad Orthop Surg* 2020; 28: 491-499.
2. Allaire R, Muriuki M, Gilbertson L, Harner CD. Biomechanical consequences of a tear of the posterior root of the medial meniscus. Similar to total meniscectomy. *J Bone Joint Surg Am* 2008; 90: 1922-1931.
3. LaPrade RF, LaPrade CM, Ellman MB, Turnbull TL, Cerminara AJ, Wijdicks CA. Cyclic displacement after meniscal root repair fixation: a human biomechanical evaluation. *Am J Sports Med* 2015; 43: 892-898.
4. Marzo JM, Gurske-DePerio J. Effects of medial meniscus posterior horn avulsion and repair on tibiofemoral contact area and peak contact pressure with clinical implications. *Am J Sports Med* 2009; 37: 124-129.
5. Krych AJ, Johnson NR, Mohan R, Hevesi M, Stuart MJ, Littrell LA, Collins MS. Arthritis Progression on Serial MRIs Following Diagnosis of Medial Meniscal Posterior Horn Root Tear. *J Knee Surg* 2018; 31: 698-704.
6. Krych AJ, Reardon PJ, Johnson NR, Mohan R, Peter L, Levy BA, Stuart MJ. Non-operative management of medial meniscus posterior horn root tears is associated with worsening arthritis and poor clinical outcome at 5-year follow-up. *Knee Surg Sports Traumatol Arthrosc* 2017; 25: 383-389.

7. Cinque ME, Chahla J, Moatshe G, Faucett SC, Krych AJ, LaPrade RF. Meniscal root tears: a silent epidemic. *Br J Sports Med* 2018; 52: 872-876.
8. Faucett SC, Geisler BP, Chahla J, Krych AJ, Kurzweil PR, Garner AM, Liu S, LaPrade RF, Pietzsch JB. Meniscus Root Repair vs Meniscectomy or Nonoperative Management to Prevent Knee Osteoarthritis After Medial Meniscus Root Tears: Clinical and Economic Effectiveness. *Am J Sports Med* 2019; 47: 762-769.
9. Kim JH, Chung JH, Lee DH, Lee YS, Kim JR, Ryu KJ. Arthroscopic suture anchor repair versus pullout suture repair in posterior root tear of the medial meniscus: a prospective comparison study. *Arthroscopy* 2011; 27: 1644-1653.
10. Kim JH, Shin DE, Dan JM, Nam KS, Ahn TK, Lee DH. Arthroscopic suture anchor repair of posterior root attachment injury in medial meniscus: technical note. *Arch Orthop Trauma Surg* 2009; 129: 1085-1088.
11. Woodmass JM, Mohan R, Stuart MJ, Krych AJ. Medial Meniscus Posterior Root Repair Using a Transtibial Technique. *Arthrosc Tech* 2017; 6: e511-e516.
12. Koga H, Nakamura T, Katagiri H, Nakagawa Y, Ozeki N, Ohara T, Shioda M, Kohno Y, Amemiya M, Sekiya I. Two-Year Outcomes After Meniscoplasty by Capsular Advancement With the Application of Arthroscopic Centralization Technique for Lateral Compartment Knee Osteoarthritis. *Am J Sports Med* 2020; 48: 3154-3162.
13. Krych AJ, LaPrade MD, Hevesi M, Rhodes NG, Johnson AC, Camp CL, Stuart MJ. Investigating the Chronology of Meniscus Root Tears: Do Medial Meniscus Posterior Root Tears Cause Extrusion or the Other Way Around? *Orthop J Sports Med* 2020; 8: 2325967120961368.
14. Page MJ, McKenzie JE, Bossuyt PM, Boutron I, Hoffmann TC, Mulrow CD, Shamseer L, Tetzlaff JM, Akl EA, Brennan SE, Chou R, Glanville J, Grimshaw JM, Hróbjartsson A, Lalu MM, Li T, Loder EW, Mayo-Wilson E, McDonald S, McGuinness LA, Stewart LA, Thomas J, Tricco AC, Welch VA, Whiting P, Moher D. The PRISMA 2020 statement: an updated guideline for reporting systematic reviews. *BMJ* 2021; 372: n71.
15. Fujii M, Furumatsu T, Kodama Y, Miyazawa S, Hino T, Kamatsuki Y, Yamada K, Ozaki T. A novel suture technique using the Fast-Fix combined with Ultrabraid for pullout repair of the medial meniscus posterior root tear. *Eur J Orthop Surg Traumatol* 2017; 27: 559-562.
16. Moon HS, Choi CH, Jung M, Lee DY, Hong SP, Kim SH. Early Surgical Repair of Medial Meniscus Posterior Root Tear Minimizes the Progression of Meniscal Extrusion: 2-Year Follow-up of Clinical and Radiographic Parameters After Arthroscopic Transtibial Pull-out Repair. *Am J Sports Med* 2020; 48: 2692-2702.
17. Kaplan DJ, Alaia EF, Dold AP, Meislin RJ, Strauss EJ, Jazrawi LM, Alaia MJ. Increased extrusion and ICRS grades at 2-year follow-up following transtibial medial meniscal root repair evaluated by MRI. *Knee Surg Sports Traumatol Arthrosc* 2018; 26: 2826-2834.
18. Ahn JH, Jeong HJ, Lee YS, Park JH, Lee JW, Ko TS. Comparison between conservative treatment and arthroscopic pull-out repair of the medial meniscus root tear and analysis of prognostic factors for the determination of repair indication. *Arch Orthop Trauma Surg* 2015; 135: 1265-1276.
19. Chung KS, Ha JK, Ra HJ, Yu WJ, Kim JG. Root Repair Versus Partial Meniscectomy for Medial Meniscus Posterior Root Tears: Comparison of Long-term Survivorship and Clinical Outcomes at Minimum 10-Year Follow-up. *Am J Sports Med* 2020; 48: 1937-1944.
20. Furumatsu T, Hiranaka T, Okazaki Y, Kintaka K, Kodama Y, Kamatsuki Y, Ozaki T. Medial meniscus posterior root repairs: A comparison among three surgical techniques in short-term clinical outcomes and arthroscopic meniscal healing scores. *J Orthop Sci* 2022; 27: 181-189.
21. Hiranaka T, Furumatsu T, Miyazawa S, Okazaki Y, Takihira S, Kodama Y, Kamatsuki Y, Masuda S, Saito T, Ozaki T. Comparison of the clinical outcomes of transtibial pull-out repair for medial meniscus posterior root tear: Two simple stitches versus modified Mason-Allen suture. *Knee* 2020; 27: 701-708.
22. Kim SB, Ha JK, Lee SW, Kim DW, Shim JC, Kim JG, Lee MY. Medial meniscus root tear refixation: comparison of clinical, radiologic, and arthroscopic findings with medial meniscectomy. *Arthroscopy* 2011; 27: 346-354.
23. Lee DW, Kim MK, Jang HS, Ha JK, Kim JG. Clinical and radiologic evaluation of arthroscopic medial meniscus root tear refixation: comparison of the modified Mason-Allen stitch and simple stitches. *Arthroscopy* 2014; 30: 1439-1446.
24. Ulku TK, Kaya A, Kocaoglu B. Suture configuration techniques have no effect on mid-term clinical outcomes of arthroscopic meniscus root repairs. *Knee* 2020; 27: 676-682.
25. Yanagisawa S, Kimura M, Hagiwara K, Ogoshi A. Association between postoperative meniscal extrusion and clinical outcomes of the pullout fixation technique for medial meniscus posterior root tear. *Asia Pac J Sports Med Arthrosc Rehabil Technol* 2020; 21: 27-31.
26. Zhang X, Furumatsu T, Okazaki Y, Hiranaka T, Kodama Y, Xue H, Ozaki T. High body mass index is a risk factor for unfavorable clinical outcomes after medial meniscus posterior root repair in well-aligned knees. *J Orthop Sci* 2021; 26: 430-434.
27. Bernard CD, Kennedy NI, Tagliero AJ, Camp CL, Saris DBF, Levy BA, Stuart MJ, Krych AJ. Medial Meniscus Posterior Root Tear Treatment: A Matched Cohort Comparison of Nonoperative Management, Partial Meniscectomy, and Repair. *Am J Sports Med* 2020; 48: 128-132.
28. Krych AJ, Johnson NR, Mohan R, Dahm DL, Levy BA, Stuart MJ. Partial meniscectomy provides no benefit for symptomatic degenerative medial meniscus posterior root tears. *Knee Surg Sports Traumatol Arthrosc* 2018; 26: 1117-1122.
29. Ro KH, Kim JH, Heo JW, Lee DH. Clinical and Radiological Outcomes of Meniscal Repair Versus Partial Meniscectomy for Medial Meniscus Root Tears: A Systematic Review and Meta-analysis. *Orthop J Sports Med* 2020; 8: 2325967120962078.
30. Daney BT, Aman ZS, Krob JJ, Storaci HW, Brady AW, Nakama G, Dornan GJ, Provencher MT, LaPrade RF. Utilization of Transtibial Centralization Suture Best Minimizes Extrusion and Restores Tibiofemoral Contact Mechanics for Anatomic Medial Meniscal Root Repairs in a Cadaveric Model. *Am J Sports Med* 2019; 47: 1591-1600.
31. Steineman BD, LaPrade RF, Haut Donahue TL. Loosening of Transtibial Pullout Meniscal Root Repairs due to Simulated Rehabilitation Is Unrecoverable: A Biomechanical Study. *Arthroscopy* 2019; 35: 1232-1239.