



CT-ARTHROGRAPHY HIGHLIGHTS INTRA-ARTICULAR PATHOLOGICAL FINDINGS IN PATIENTS AFFECTED BY RECALCITRANT LATERAL ELBOW PAIN

P. ARRIGONI¹, D. CUCCHI², M. RADICI¹, V. VISMARA³, S. CASSIN³,
F. LUCERI¹, A. MENON¹, A. TRAVERSO^{1,4}, C. KOUKOS⁵, M. ARCHINÀ³,
A. ZAGARELLA⁶, P.S. RANDELLI⁷⁻⁹

• • •

¹Clinica Ortopedica, Azienda Socio-Sanitaria Territoriale Centro Specialistico Ortopedico Traumatologico
Gaetano Pini-CTO, Milan, Italy

²Department of Orthopedics and Trauma Surgery, Universitätsklinikum Bonn, Bonn, Germany

³Scuola Di Specializzazione in Ortopedia e Traumatologia, Università degli Studi di Milano, Milan, Italy

⁴Service D'orthopédie et de Traumatologie, Centre Hospitalier Universitaire Vaudois (CHUV),
Lausanne, Switzerland

⁵Sports Trauma & Pain Institute, Thessaloniki, Greece

⁶U.O.C. Radiodiagnostica, Azienda Socio-Sanitaria Territoriale Centro Specialistico Ortopedico Traumatologico
Gaetano Pini-CTO, Milan, Italy

⁷Department of Biomedical Sciences for Health, Laboratory of Applied Biomechanics,
Università degli Studi di Milano, Milan, Italy

⁸Department of Biomedical Sciences for Health, Research Center for Adult and Pediatric Rheumatic Diseases
(RECAP-RD), Università degli Studi di Milano, Milan, Italy

⁹U.O.C. 1° Clinica Ortopedica, ASST Centro Specialistico Ortopedico Traumatologico Gaetano Pini-CTO, Milan, Italy

P. Arrigoni, D. Cucchi, A. Zagarella and P.S. Randelli contributed equally to this work

CORRESPONDING AUTHOR

Paolo Arrigoni, MD; e-mail: arrigoni.p@gmail.com

ABSTRACT – Objective: Degeneration and tendinosis of the common extensor origin, specifically the extensor carpi radialis brevis, are generally considered the main causes of lateral epicondylitis. Recent evidence suggests that the extra-articular/tendon-related source could not be the sole cause of lateral elbow pain but also part of a multifactorial process involving intra-articular causes and factors. The purpose of this study is to have new data comparing the prevalence of radiological signs of intra-articular pathology detectable with CT arthrography in patients with and without symptoms of recalcitrant lateral elbow pain. In addition, this study aims to evaluate and propose a new diagnostic tool for symptomatic minor instability of the lateral elbow (SMILE) condition based on arthro-CT images. Do patients with SMILE present more radiological signs detectable with CT arthrography compared to asymptomatic ones?



Patients and Methods: Patients with painful elbow conditions requiring 2nd level diagnostic investigation with CT-arthrography in flexion were included. Exclusion criteria were the presence of bony injuries, major cartilage lesions, and gross ligamentous pathology or clinical history of infection, trauma, deformity, or major instability. Eligible patients were divided into two groups depending on the presence (cases) or absence (controls) of clinical symptoms of lateral recalcitrant elbow pain. Ninety patients were included, and 62 presented lateral recalcitrant elbow pain. The presence and prevalence of four distinct signs of intra-articular pathology were documented.

Results: Synovitis was the most frequently reported finding (83.3%) with CT arthrography in flexion. The presence of at least two findings was significantly higher ($p = 0.0160$) in patients with recalcitrant lateral elbow pain (74.2%) than in patients without recalcitrant lateral elbow pain (46.4%). Three and four intra-articular findings were found to be significantly more frequent in cases than in controls ($p = 0.0002$ and 0.0179 , respectively). These results confirm the study hypothesis.

Conclusions: Patients with lateral recalcitrant elbow pain show a high prevalence of signs of intra-articular pathology, which can be radiologically detected using CT arthrography. This is a valid diagnostic tool and should be implemented in the evaluation of all patients complaining of lateral elbow pain. The presence of two intra-articular findings is suggested as a diagnostic cut-off to define intra-articular pathology as the cause of symptomatic SMILE patients.

KEYWORDS: Recalcitrant lateral elbow pain, SMILE, Diagnostic evaluation, CT-arthrography, Epicondylitis.

INTRODUCTION

Degeneration and tendinosis of the common extensor origin, specifically the extensor carpi radialis brevis (ECRB), are generally considered the main causes of lateral epicondylitis, or tennis elbow. However, recent evidence¹ suggests that the extra-articular/tendon-related source could not be the sole source of lateral elbow pain but part of a multifactorial process involving extra-articular as well as intra-articular and systemic factors. The association of a high prevalence of intra-articular pathological findings to laxity or degeneration of the radial band of the lateral collateral ligament complex (R-LCL) in patients affected by recalcitrant lateral elbow pain leads to the development of the symptomatic minor instability of the lateral elbow (SMILE) concept, in which a deficiency or insufficiency of this static varus stabilizer is postulated to have a pathological relevance². This concept is well supported by biomechanical and operative findings. Nevertheless, clinical, pre-operative diagnostic tools to evaluate the presence of intra-articular pathologies before arthroscopy are lacking and limited to pilot studies and technical descriptions³⁻⁵. The identification of a suitable imaging technique to accurately identify intra-articular pathologies before surgery is, therefore, of paramount importance for appropriate surgical planning and patient counseling.

This study aims to compare the prevalence of intra-articular pathologies on advanced imaging in patients with and without symptoms of recalcitrant lateral elbow pain (r-LEP), evaluate and propose a new diagnostic tool for the SMILE concept based on arthro-CT images, and hypothesize that patients with SMILE present more radiological signs detectable with CT arthrography compared to asymptomatic ones.

PATIENTS AND METHODS

Before commencing the study, the study protocol was approved by the Gaetano Pini Institute Ethics Committee (resolution No. 138, dated 18 March 2021 – approval No. 233_2021).

Inclusion and Exclusion Criteria

Consecutive patients referred and examined by the first author for painful elbow conditions were considered for retrospective enrolment between April 2019 and October 2022. Patients with a documented previous history of infection, acute trauma, deformity, rheumatoid arthritis, or with clinical signs of gross ligamentous instability (positive posterolateral drawer, posterolateral pivot shift, and

varus/valgus stress tests) were excluded. Patients between 18 and 70 years of age were included if a 1st-level diagnostic investigation with ultrasound was inconclusive and deemed insufficient to reach a diagnosis or suggest an appropriate treatment, thus requiring a 2nd-level investigation. CT-arthrography with the elbow flexed was performed as a 2nd-level investigation to look for cartilage defects, osteochondral lesions, ligamentous elongation, and intra-articular loose bodies and to rule out bony injuries.

CT-Arthrography with the Elbow in Flexion

This specific 2nd level investigation is the standard advanced imaging at our institution and was chosen since it provides better spatial resolution, lower acquisition times, and equivalent diagnostic accuracy to MR-arthrography for the detection of cartilage defects, osteochondral lesions, and intra-articular loose bodies while exposing the patient to a low dose of ionizing radiation⁶. After injection of 5-7 mL of iodinated contrast agent (Iopamidol 33 mg/mL) in the olecranon fossa performed by a radiologist, spiral CT is performed (GE Revolution EVO 64-slice CT scanner, GE Healthcare, Chicago, IL, USA) with the patient prone on the scanning table, with the affected limb elevated over the head and the elbow flexed 45°⁵.

Axial 1.25 mm slice-thickness images are obtained and reconstructed in axial, coronal, and sagittal planes. All analyses were performed by an independent specialized musculoskeletal radiologist.

The presence of four areas of intra-articular pathology related to the lateral aspect of the elbow was documented as follows:

- 1) Synovitis anterior or posterior to the radial head (Figure 1).
- 2) Chondral lesions at the level of the radiocapitellar joint, either in the form of erosive changes in the lateral half of the radial head circumference [chondral erosion of the lateral aspect of the radial head (CLEAR)] or in the form of cartilage delamination of the most lateral part of the capitellum [chondropathy of the lateral aspect of the capitellum (CLAC)] (Figures 2 and 3)^{2,5}.
- 3) A leakage of contrast agent through lateral ligamentous structures is considered a sign of a lateral capsular lesion (Figure 3).
- 4) A hyperdistention of the annular ligament with loss of the physiological adhesion of this ligament to the radial neck and deformation of the fibers, which appears curve-shaped instead of linear, but without evidence of fiber tearing [loose collar sign (LCS)], possibly associated with bulging of the lateral capsule with loss of linear signal (ballooning) (Figures 3 and 4)².

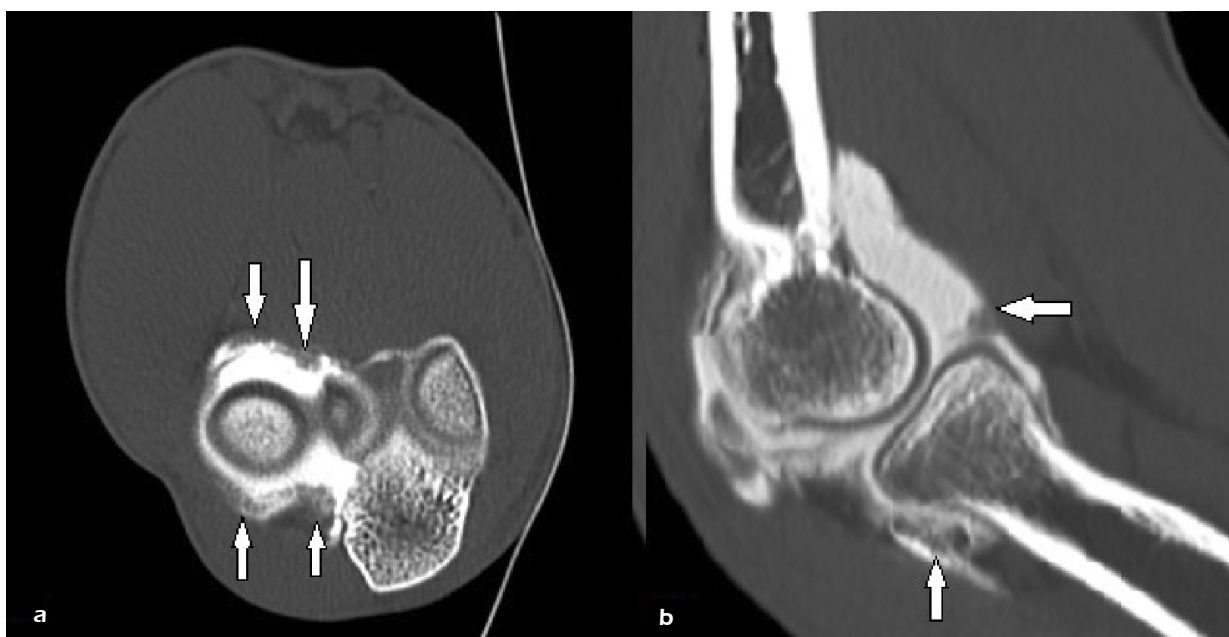

Figure 1. Axial (a) and sagittal (b) CT-arthrography images showing a synovial thickening at the anterior and posterior aspect of the radial head (white arrows).

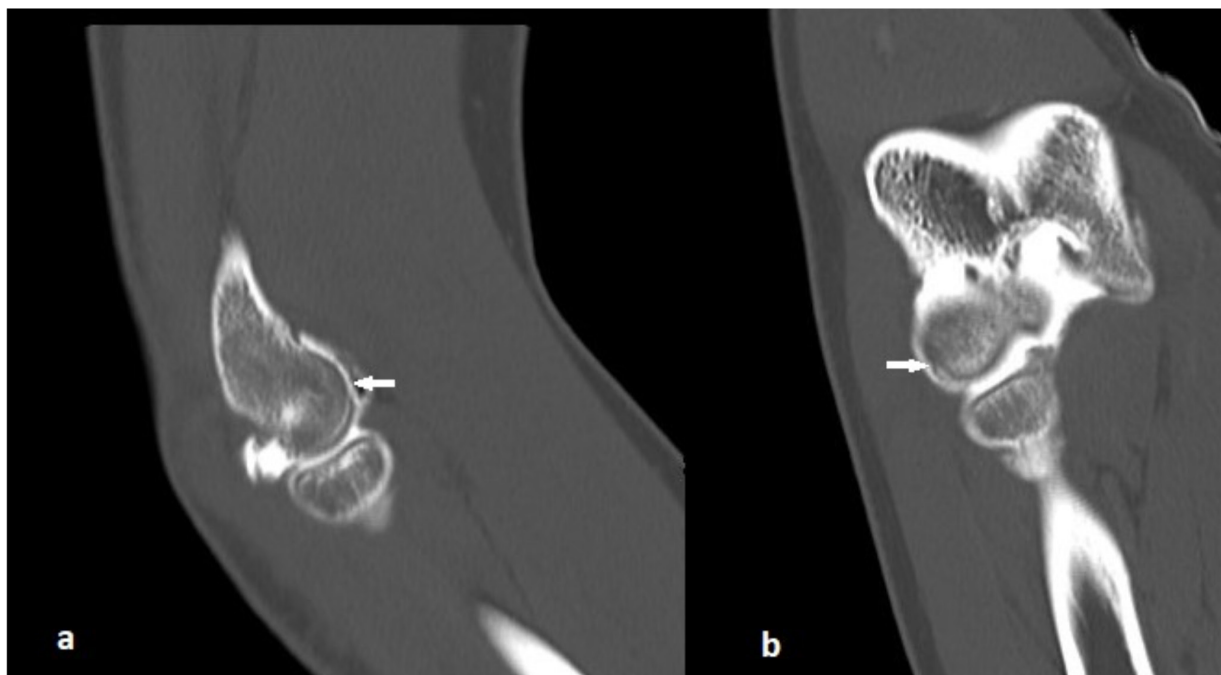


Figure 2. Sagittal (a) and coronal (b) CT-arthrography images demonstrating a chondral erosion of the lateral aspect of the capitellum, i.e., CLAC (white arrows).

Patient Allocation and Subgroup Analysis

Patients were classified into two groups depending on the presence or absence of clinical symptoms of r-LEP, as documented during the clinical investigation. Patients were assigned to the r-LEP group (study group) if complaining of lateral elbow pain non-responsive to conservative treatment (rest, steroid and/or collagen injections, shock wave therapy, physical therapy) for more than 3 months and physical exam demonstrated tenderness at the level or just below the lateral epicondyle and positive tests for lateral

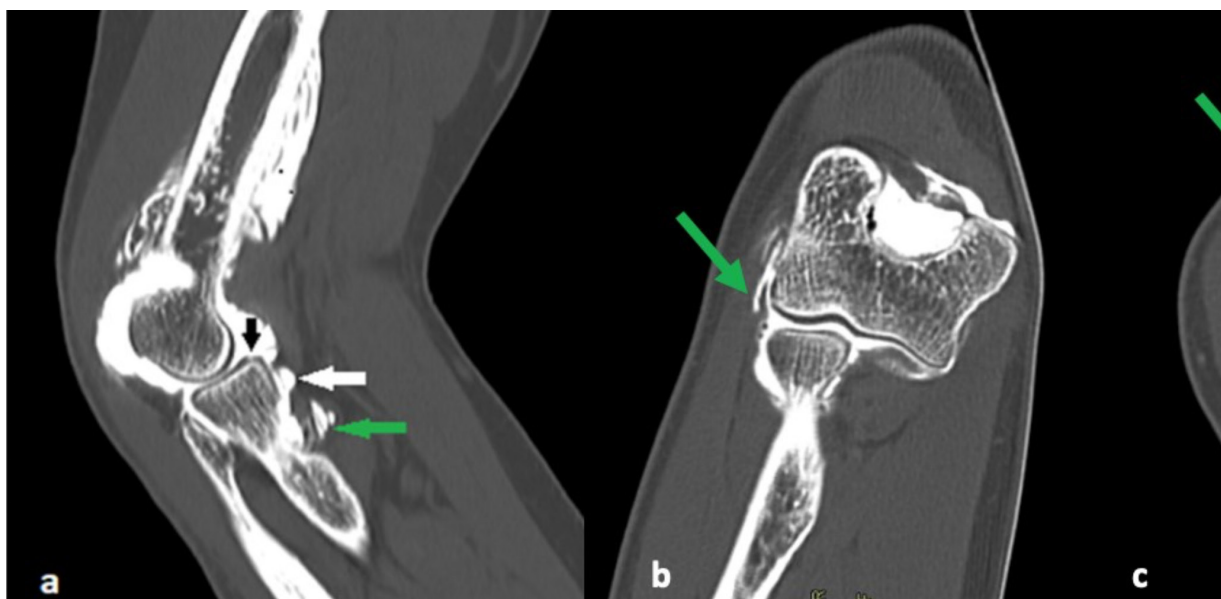
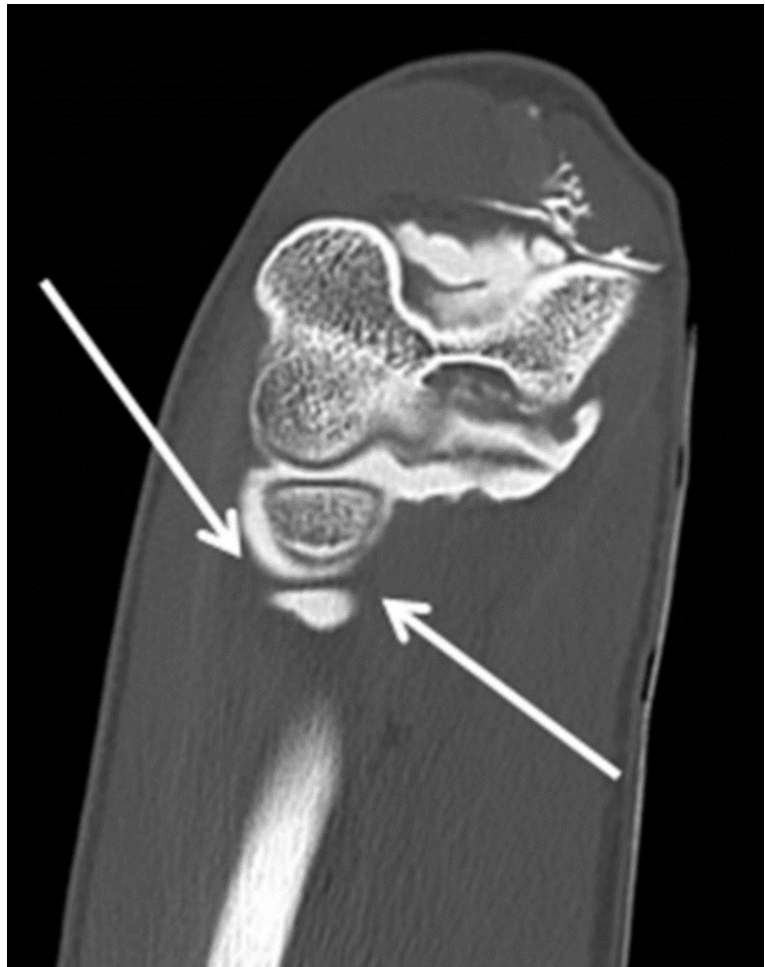


Figure 3. Sagittal (a), coronal (b), and axial (c) CT-arthrography images demonstrating a chondral erosion of the lateral-anterior aspect of the radial head, i.e., CELAR (black arrow). Furthermore, the annular ligament is detached and distally displaced (white arrow), with a contrast agent leaking through its fibers, suggesting a capsuloligamentous tear (green arrows).

Figure 4. Coronal CT-arthrography image showing a markedly widened lateral compartment, suggestive of patholaxity, as the annular ligament presents a curved shape and is caudally displaced (white arrows). No contrast agent extravasation is noted in this scan.



intra- or extraarticular pathology^{3,7}. Patients not complaining of r-LEP and having undergone CT-arthrography in flexion for other painful elbow conditions with the inconclusive 1st-level diagnostic investigation were allocated to the control group.

Clinical findings were documented as precisely and objectively as possible in a standardized fashion by the first author.

Statistical Analysis

Demographic data, as well as data regarding the diagnosis and treatment of elbow pathology and information on CT-arthrography findings, were entered into a spreadsheet for analysis.

Statistical analysis was performed using GraphPad Prism v. 6.0 software (GraphPad Software Inc., La Jolla, CA, USA). The relative prevalence of the reported findings was calculated. The Shapiro-Wilk normality test was used to evaluate the normal distribution of the sample. Continuous variables were expressed as the mean \pm standard deviation (SD) or medians and first and third quartiles [Q1-Q3], as appropriate. Categorical variables were expressed in several cases and frequencies. Differences between groups were evaluated with unpaired Student's *t*-test or Mann-Whitney test according to the characteristics of the data distribution for continuous variables and Chi-squared test or Fisher's exact test for categorical ones. For all analyses, the significance level was set at a *p*-value lower than 0.05.

It was hypothesized that at least two relevant intra-articular pathological findings would be present in more than 50% of patients presenting with r-LEP, whereas this percentage was expected to drop below 50% in patients without r-LEP that underwent CT-arthrography for other reasons. A sample size of 61 cases was considered sufficient to evaluate a difference in the prevalence of at least two relevant radiological findings in the study group greater than 25% as compared to controls without r-LEP (expected prevalence in the group without r-LEP: < 50%, power of 80%, significance level set at 5%, one-sided Student's *t*-test, sampling ratio set at 0.5).

RESULTS

One hundred twenty consecutive patients were evaluated and ninety were included in this study (age: 45.3 ± 11.7 , females: 37.8%). Thirty of 120 patients had at least one exclusion criterion (25% of patients). The right limb was affected in 53 patients (58.9%). Symptoms related to the lateral aspect of the elbow were documented in 62 cases (68.9 %; age: 47.4 ± 11.1 , females: 40.3%).

The study included a total of 90 patients, 62 of whom experienced persistent lateral elbow pain, while the remaining 28 did not exhibit this symptom. Within the study group, synovitis was the most frequently reported finding (83.3%), followed by signs of hyperdistention of the annular ligament with or without abnormal widening and ballooning of the lateral capsule (53.3%). The prevalence of all intra-articular findings was more frequent in the group referring to r-LEP. Figure 5 illustrates the distribution of the findings in the different study subgroups (total population, patients with r-LEP, and patients without r-LEP). The presence of at least two findings was documented in 46.4% of patients without r-LEP and 74.2% of those with r-LEP, thus confirming the study hypothesis. Comparing the groups with and without r-LEP, the presence of at least two, three, and four findings was found to be significantly more frequent in cases than in controls ($p = 0.0160$, $p = 0.0002$, and 0.0179 , respectively).

After synovitis, the most frequently encountered findings were related to laxity of the lateral compartment, consisting in a visible loss of the linear signal of the annular ligament defined as an LCS, which can be associated with abnormal hyperdistention of this band as well as widening and ballooning of the lateral capsule (Figure 4).

The presence of r-LEP was associated with higher odds of presenting positive intra-articular findings (Table 1). These data suggest considering the presence of two intra-articular findings as a diagnostic cut-off to define intra-articular pathology associated with r-LEP.

DISCUSSION

The main finding of this study is that patients with lateral recalcitrant elbow pain show a high prevalence of intra-articular pathological signs, which can be radiologically detected using CT arthrography. This

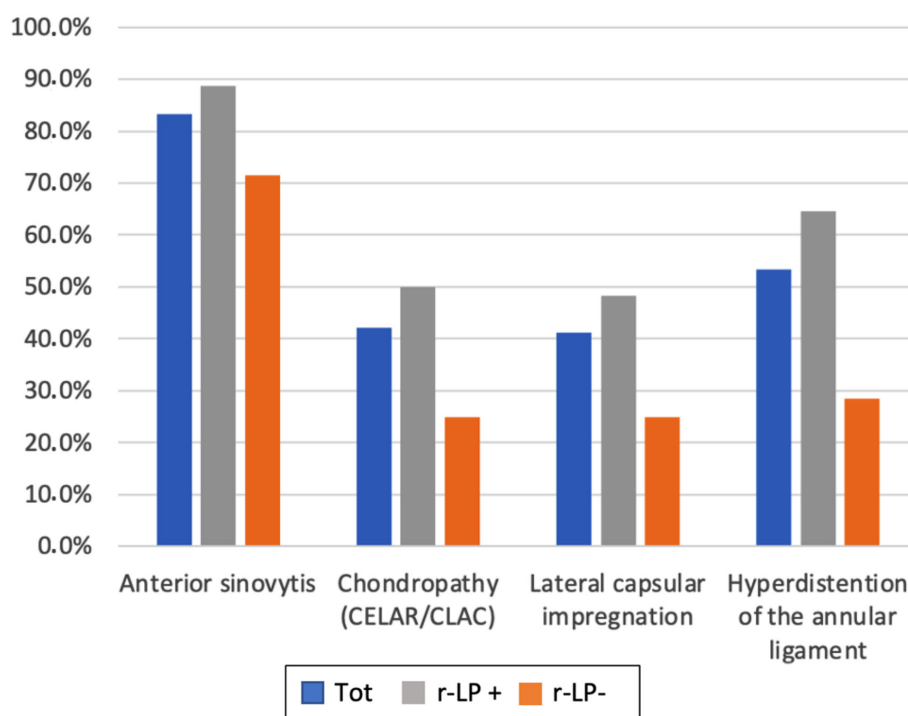


Figure 5. Bar chart illustrating the prevalence of the four investigated intra-articular CT-arthrography findings in the study population, irrespectively of the symptomatology (blue bars), in patients having clear recalcitrant lateral elbow pain symptomatology (r-LEP +, grey bars) and in patients with a negative history of recalcitrant lateral elbow pain symptomatology (r-LEP-, orange bars).

Table 1. Odds ratio (OR) and 95% confidence intervals (CI) for the likelihood of presenting more than one CT-arthrography intra-articular finding in cases compared to controls.

	OR	[95% CI]
Two findings	3.27	[1.17-9.37]
Three findings	6.66	[2.11-25.48]
Four findings	8.47	[1.18-375.3]

high prevalence of intra-articular findings in patients affected by recalcitrant lateral elbow pain is not encountered in controls lacking lateral elbow symptoms.

The higher frequency of radiological findings indicative of insufficiency of the lateral capsuloligamentous structures in patients with r-LEP supports the previous arthroscopic descriptions of intra-articular findings related to SMILE condition². Furthermore, this study showed that CT-arthrography is a valid diagnostic tool able to identify specific pathological changes in patients affected by r-LEP, thus proving to be suitable imaging for diagnosing SMILE. Our data indicate that the presence of two intra-articular findings should be used as a diagnostic cut-off rule for diagnosing SMILE.

Minor instabilities resulting from repetitive low-energy stress or shear have been found in several joints and are generally characterized by chondral damage, tendonitis, capsular pathology, and abnormal ligamentous laxity^{2,8-12}. This model is gaining popularity, and an increasing number of reports^{4,13-15} are being published, reporting on arthroscopic and radiological findings of R-LCL abnormalities in patients affected by r-LEP. The biomechanical stabilizing role of this broad, diamond-shaped ligament has been postulated in clinical studies and confirmed in biomechanical tests, demonstrating that R-LCL insufficiency could overload the dynamic stabilizers, especially under varus load, provoking inflammation and pain at the level of the ECRB insertion, which is located just extra-capsular and parallel to R-LCL^{2,16-19}.

This study adds significant evidence to the portfolio of preoperative diagnostic techniques useful for detecting lateral capsuloligamentous insufficiency. Ultrasound investigation has been extensively used to evaluate muscular and tendinous injuries of the elbow, mainly focusing on major medial and posterolateral instabilities²⁰. Nevertheless, although the US investigation was demonstrated to effectively visualize both the U-LCL and the R-LCL, it does not appear to be sufficient to identify direct or indirect signs of R-LCL pathology^{4,21}.

Second-level diagnostics, such as CT and MRI, can help visualize bony, cartilage, and ligamentous structures with a high spatial resolution; in particular, the intra-articular injection of contrast medium can greatly enhance the visualization of intra-articular structures^{4,22}. As compared to MR-arthrography, CT-arthrography provides better spatial resolution and lower acquisition times, with similar diagnostic accuracy when evaluating osteochondral lesions, cartilage defects, and intra-articular loose bodies⁶. The flexed elbow position was chosen to perform this investigation because it avoids tensioning the anterior and lateral capsuloligamentous structures, thus permitting contrast medium to penetrate between the radial head, capsule, and annular ligament, showing any abnormal distention of these structures⁴. Furthermore, being in the same position where arthroscopic procedures are conducted, it is considered advantageous for the translation of radiological findings in the clinical setting⁴. Herewith, the results of this study encourage the implementation of CT-arthrography in the diagnostic evaluation of all patients complaining of recalcitrant lateral elbow pain, considering the presence of two intra-articular findings as a diagnostic cutoff rule in the diagnosis of a SMILE.

Limitations

This study has several limitations. First, the population was composed of a relatively small number of Caucasian patients, which could limit the statistical power of our conclusion and should be considered before extrapolating the significant findings to the general population. Second, this study focused primarily on the relationship between clinical tests and radiological findings. However, it is worth remembering that these intra-articular elements may coexist with extra-articular/tendon-related pathologic elements and with systemic factors.

CONCLUSIONS

Patients with lateral recalcitrant elbow pain show a high prevalence of intra-articular pathology signs, which can be radiologically detected using CT-arthrography, such as anterior synovitis, hyperdistention of the annular ligament, radiocapitellar chondropathy and lateral capsular lesions. The presence of two intra-articular findings is suggested as a diagnostic cut-off to define intra-articular pathology associated with recalcitrant lateral elbow pain and herewith to rule in the diagnosis of SMILE. CT-arthrography is a valid diagnostic tool and should be implemented in the diagnostic evaluation of all patients complaining of recalcitrant lateral elbow pain.

ETHICS APPROVAL:

Ethics approval for the study protocol was obtained from the Gaetano Pini Institute Ethics Committee before commencing the study (resolution No. 138, dated 18 March 2021 – approval No. 233_2021).

INFORMED CONSENT:

Not applicable due to the retrospective nature of the study.

CONFLICT OF INTEREST:

The authors have no conflicts of interest to declare.

FUNDING:

This research was not funded.

AI DISCLOSURE:

The datasets generated during and/or analyzed during the current study are available from the corresponding author upon reasonable request.

ORCID ID:

Paolo Arrigoni: 0000-0002-8273-9823

AUTHORS' CONTRIBUTIONS:

PA: conception and design of the study; acquisition of data; analysis and interpretation of data; drafting the article; making critical revisions related to the relevant intellectual content of the manuscript; supervision; validation and final approval of the version of the article to be published.

DC: conception and design of the study; acquisition of data; analysis and interpretation of data; drafting the article; making critical revisions related to the relevant intellectual content of the manuscript; supervision; validation and final approval of the version of the article to be published.

MR: conception and design of the study, acquisition of data.

VV: drafting the article, analysis and interpretation of data.

SC: drafting the article, analysis and interpretation of data.

FL: conception and design of the study, supervision, validation, and final approval of the version of the article to be published.

AM: analysis and interpretation of data.

AT: drafting the article and making critical revisions related to the relevant intellectual content of the manuscript.

CK: drafting the article.

MA: drafting the article, analysis and interpretation of data.

AZ: acquisition of data, analysis, and interpretation of data, supervision, validation, and final approval of the version of the article to be published.

PSR: acquisition of data, analysis and interpretation of data, supervision, validation, and final approval of the version of the article to be published.

AVAILABILITY OF DATA AND MATERIALS:

The datasets generated during and/or analyzed during the current study are available from the corresponding author upon reasonable request.

REFERENCES

1. Dines JS, Bedi A, Williams PN, Dodson CC, Ellenbecker TS, Altchek DW, Windler G, Dines DM. Tennis injuries: epidemiology, pathophysiology, and treatment. *J Am Acad Orthop Surg* 2015; 23: 181-189.
2. Arrigoni P, Cucchi D, D'Ambrosi R, Butt U, Safran MR, Denard P, Randelli P. Intra-articular findings in symptomatic minor instability of the lateral elbow (SMILE). *Knee Surg Sports Traumatol Arthrosc* 2017; 25: 2255-2263.
3. Arrigoni P, Cucchi D, Menon A, Randelli P. It's time to change perspective! New diagnostic tools for lateral elbow pain. *Musculoskelet Surg* 2017; 101: 175-179.
4. Nocerino EA, Cucchi D, Arrigoni P, Brioschi M, Fusi C, Genovese EA, Messina C, Randelli P, Masciocchi C, Aliprandi A. Acute and overuse elbow trauma: Radio-orthopaedics overview. *Acta Biomed* 2018; 89: 124-137.
5. Zagarella A, Signorelli G, Muscogiuri G, Colombo R, Folco G, Arrigoni P, Radici M, Randelli PS, Gallazzi MB. Overuse-related instability of the elbow: the role of CT-arthrography. *Insights Imaging* 2021; 12: 140.
6. Delport AG, Zoga AC. MR and CT arthrography of the elbow. *Semin Musculoskelet Radiol* 2012; 16: 15-26.
7. Cozen L. The painful elbow. *Ind Med Surg* 1962; 31: 369-371.
8. Caprise PA, Sekiya JK. Open and arthroscopic treatment of multidirectional instability of the shoulder. *Arthroscopy* 2006; 22: 1126-1131.
9. Caggiano N, Matullo KS. Carpal instability of the wrist. *Orthop Clin North Am* 2014; 45: 129-140.
10. Castagna A, Nordenson U, Garofalo R, Karlsson J. Minor shoulder instability. *Arthroscopy* 2007; 23: 211-215.
11. Boileau P, Zumstein M, Balg F, Penington S, Bicknell RT. The unstable painful shoulder (UPS) as a cause of pain from unrecognized anteroinferior instability in the young athlete. *J Shoulder Elbow Surg* 2011; 20: 98-106.
12. Burkhart SS, Morgan CD, Ben Kibler W. The disabled throwing shoulder: Spectrum of pathology Part I: Pathoanatomy and biomechanics. *J Arthrosc Relat Surg* 2003; 19: 404-420.
13. Cha YK, Kim SJ, Park NH, Kim JY, Kim JH, Park JY. Magnetic resonance imaging of patients with lateral epicondylitis: Relationship between pain and severity of imaging features in elbow joints. *Acta Orthop Traumatol Turc* 2019; 53: 366-371.
14. Aydoğmuş S, Mete BD, Aydoğmuş H, Uluç ME, Tosun Ö, Çetinoğlu YK. Investigation of ligament, bone, synovial and plica pathologies accompanied by common extensor tendon in patients with lateral overuse syndrome of the elbow using magnetic resonance imaging. *Acta Radiol* 2022; 63: 214-221.
15. Arrigoni P, Cucchi D, D'Ambrosi R, Menon A, Aliprandi A, Randelli P. Arthroscopic R-LCL plication for symptomatic minor instability of the lateral elbow (SMILE). *Knee Surgery, Sport Traumatol Arthrosc* 2017; 25: 2264-2270.
16. Ciaudo O, Guérin-Surville H. [Importance of damage to the medial fascia of the external lateral ligament (radial collateral ligament) in the mechanisms of luxations of the elbow. Study on the cadaver (author's transl)]. *J Chir (Paris)* 1980; 117: 237-239.
17. Cohen MS, Hastings H. Rotatory instability of the elbow. The anatomy and role of the lateral stabilizers. *J Bone Joint Surg Am* 1997; 79: 225-233.
18. Arrigoni P, Cucchi D, Luceri F, Menon A, Zaolino C, Zagarella A, Catapano M, Radici M, Migliaccio N, Polli D, Randelli PS. Lateral Elbow Laxity Is Affected by the Integrity of the Radial Band of the Lateral Collateral Ligament Complex: A Cadaveric Model With Sequential Releases and Varus Stress Simulating Everyday Activities. *Am J Sports Med* 2021; 49: 2332-2340.
19. Lannes X, Traverso A, Wehrli L, Goetti P. [Support algorithm for lateral elbow pain syndrome in adults]. *Rev Med Suisse* 2023; 19: 2336-2343.
20. Bachta A, Rowicki K, Kisiel B, Żabicka M, Elert-Kopeć S, Płomiński J, Tłustochowicz W, Maliborski A. Ultrasonography versus magnetic resonance imaging in detecting and grading common extensor tendon tear in chronic lateral epicondylitis. *PLoS One* 2017; 12: e0181828.
21. Luceri F, Cucchi D, Rosagrata E, Zaolino CE, Viganò M, de Girolamo L, Zagarella A, Catapano M, Gallazzi MB, Arrigoni PA, Randelli PS. Novel Radiographic Indexes for Elbow Stability Assessment: Part A-Cadaveric Validation. *Indian J Orthop* 2021; 55: 336-346.
22. Arrigoni P, Cucchi D, Luceri F, Zagarella A, Catapano M, Menon A, Bruno V, Gallazzi M, Randelli PS. Ultrasound evaluation shows increase in laxity after partial common extensor origin detachment but not after additional lesion of the radial band of the lateral collateral ligament. *Knee Surg Sports Traumatol Arthrosc* 2021; 29: 4067-4074.