



ARTHROSCOPIC MANAGEMENT OF HIP SYNOVIAL CHONDROMATOSIS: A SYSTEMATIC REVIEW OF CLINICAL OUTCOMES AND RECURRENCE RATES

R. GIAI VIA¹, A. ELZEINY², S. PANTÈ¹, C. DE FRANCO³, F. GIUSTRA³,
F. BOSCO^{4,5}, K. ZOCCOLA³, A. MASSÈ^{1,6}, A. APRATO^{1,7}

• • •

¹Department of Surgical Sciences, Orthopedic and Traumatology Surgery Residency, University of Turin, Turin, Italy

²Department of Orthopedics and Traumatology, Faculty of Medicine, Kafr El Sheikh University, Kafr El Sheikh, Egypt

³Department of Orthopedics and Traumatology, San Giovanni Bosco Hospital - ASL City of Turin, Turin, Italy

⁴Department of Precision Medicine in Medical, Surgical and Critical Care (Me.Pre.C.C.), University of Palermo, Palermo, Italy

⁵Department of Orthopedics and Traumatology, ASP 6, P.O. Ingrassia, Palermo, Italy

⁶Department of Orthopedic Surgery, Centro Traumatologico Ortopedico (CTO), Turin, Italy

⁷Department of Pediatric Orthopedic and Traumatology Surgery, Regina Margherita Children's Hospital, Turin, Italy

CORRESPONDING AUTHOR

Francesco Bosco, MD, Ph.Dst; e-mail: francesco.bosco03@unipa.it

ABSTRACT – Objective: Synovial chondromatosis (SC) of the hip is a rare benign condition caused by intra-articular cartilaginous nodules, which may lead to secondary osteoarthritis (OA). Arthroscopic treatment (AT) is increasingly used as a minimally invasive option. This systematic review aimed to evaluate the efficacy, safety, and recurrence rates of AT for hip SC, focusing on clinical outcomes, complications, and the need for revision surgery.

Materials and Methods: A systematic literature search was performed across PubMed, Scopus, Embase, MEDLINE, and Cochrane databases up to December 2024, following PRISMA guidelines. Clinical studies on arthroscopic treatment of hip SC in humans, published from 2000 to 2024, with ≥22 months of follow-up and levels of evidence I-IV were included. Thirteen studies with 369 patients were analyzed. Methodological quality was assessed using the Oxford level of evidence (LoE) and modified Coleman Methodology Score (mCMS). Extracted data included demographics, surgical technique, clinical outcomes, complications, and recurrence.

Results: The review included 369 patients (mean age 26.7-45.1 years; predominantly male). Arthroscopic treatment led to significant improvements in functional outcomes, with marked increases in modified Harris Hip Score (mHHS), International Hip Outcome Tool (iHOT12), Non-Arthritic Hip Score (NAHS) scores, and pain reduction on Visual Analogue Scale (VAS). Patient-reported satisfaction ranged from 75% to 100%. The overall recurrence rate was 22.7%, with 38 patients undergoing repeated arthroscopy and 44 requiring open revision surgery. Progression to end-stage OA occurred in 7.3% of cases, necessitating total hip arthroplasty. Reported complications were infrequent and mostly minor, including transient neuropraxia and perineal numbness. Synovectomy combined with loose body removal provided durable clinical benefit in most patients, particularly when complete debridement was achieved.



Conclusions: Arthroscopic treatment is a safe and effective option for hip SC, providing durable symptom relief, high satisfaction, and acceptable recurrence. Accurate diagnosis, staging, and patient selection are essential. Standardized protocols are needed to optimize outcomes.

KEYWORDS: Synovial chondromatosis, Hip arthroscopy, Arthroscopy, Hip preservation, Hip joint.

INTRODUCTION

Synovial chondromatosis (SC) is a rare, benign condition of unknown etiology, characterized by the formation of cartilaginous nodules within the synovial membrane of joints, bursae, or tendon sheaths^{1,2}. The disease typically progresses through three stages: initial synovial proliferation without loose bodies, a transitional phase with both active synovitis and loose bodies, and a late phase dominated by intra-articular loose bodies with quiescent synovium¹. These nodules can detach and migrate within the joint, potentially leading to mechanical damage of the articular cartilage and secondary osteoarthritis (OA)². SC most commonly affects males between the third and fifth decades of life, with a male-to-female ratio of approximately 2:1³.

While the knee is the most frequently involved site, SC can also affect other joints, including the hip, elbow, wrist, and temporomandibular joint¹. Although typically intra-articular, extra-articular manifestations involving tendon sheaths and bursae have been reported². In the hip, SC presents with non-specific symptoms such as groin pain, crepitus, reduced range of motion (ROM), and joint tenderness, often mimicking early OA^{1,3}. Conventional radiographs may reveal calcified nodules in approximately 70% of cases⁴, though early-stage disease may lack detectable calcifications⁵. Advanced imaging modalities like computed tomography (CT) or magnetic resonance imaging (MRI) are indicated when standard radiographs are inconclusive⁵. MRI, in particular, provides superior soft tissue contrast, allowing for the identification of non-calcified loose bodies, synovial thickening, and disease extent⁶.

Open surgical dislocation of the hip, as described by Ganz et al⁷, remains a valid approach for SC treatment, offering direct visualization of the joint while preserving the femoral head blood supply. However, the advent of advanced arthroscopic techniques (ATs) has led to a paradigm shift, favoring minimally invasive management due to lower morbidity and faster recovery⁸. Arthroscopic procedures typically involve the removal of intra-articular loose bodies, with partial or complete synovectomy depending on the extent of synovial involvement^{9,10}. Loose body removal alone may suffice in limited disease, whereas extensive synovial proliferation requires synovectomy to reduce recurrence risk and achieve durable symptom relief¹¹. Arthroscopic treatment has demonstrated promising outcomes in terms of pain reduction, functional improvement, and recurrence prevention⁹⁻¹¹.

The aim of this systematic review is to critically evaluate the clinical outcomes, complication rates, and risk of recurrence associated with arthroscopic treatment of hip SC, with the goal of defining its effectiveness and indications based on current evidence.

MATERIALS AND METHODS

Research Question

This systematic review was conducted according to the Preferred Reporting Items for Systematic Reviews and Meta-Analyses (PRISMA) guidelines to ensure the rigorous identification and selection of relevant studies¹². Two independent reviewers (RGV and AE) performed the search and screening processes to minimize potential bias. In case of disagreement, a third reviewer (FG) was consulted to resolve any uncertainties.

Inclusion and Exclusion Criteria

Studies were eligible for inclusion if they involved patients undergoing arthroscopic surgery for hip SC. To be considered, studies had to involve human subjects, be published between 2000 and December 2024, and report a minimum follow-up of 22 months, with a level of evidence (LoE) ranging from 1 to 4. Excluded papers comprised biochemical studies, *in vitro* research, case reports, editorials, book chapters, technical notes, preclinical studies, and studies with LoE 5.

Search Strategy and Study Screening

A comprehensive search was conducted in five databases (PubMed, Scopus, Embase, Cochrane, and MEDLINE) using the following MeSH terms: ((synovial chondromatosis) OR (chondromatosis)) AND (ar-

throsopic*) AND (hip). A total of 364 articles were identified. After removing duplicates, 184 articles remained. Titles and abstracts were screened, resulting in the exclusion of 168 studies. Sixteen articles underwent full-text review, of which 13 met the inclusion criteria and were selected for qualitative analysis. The selected studies provided data on patient positioning, arthroscopic portals, postoperative protocols, functional outcomes, time to symptom resolution, complications, and revision rates in patients treated with ATs for hip SC. The selection process is illustrated in the PRISMA flowchart (Figure 1).

Methodological Quality Assessment

The quality of the included studies was evaluated using the 2011 Oxford Centre for Evidence-Based Medicine Levels of Evidence framework¹³. Studies were graded from level 1 (highest) to level 5. Retrospective studies were further assessed using the modified Coleman Methodology Score (mCMS), as adapted from Ramponi et al¹⁴ (Figure 2). Complications were categorized according to the Clavien-Dindo classification¹⁵. This systematic review was registered in the International Registry of Systematic Reviews (PROSPERO), under the ID CRD420250652745, in February 2025¹⁶.

Data Extraction

Data from the included studies were extracted systematically using a standardized template. Extracted variables included authorship, year of publication, study design, sample size, mean patient age, radiographic findings, arthroscopic portals used, and mean operative time. Clinical outcomes were assessed using pre- and postoperative scores, including the modified Harris Hip Score (mHHS), Harris Hip Score

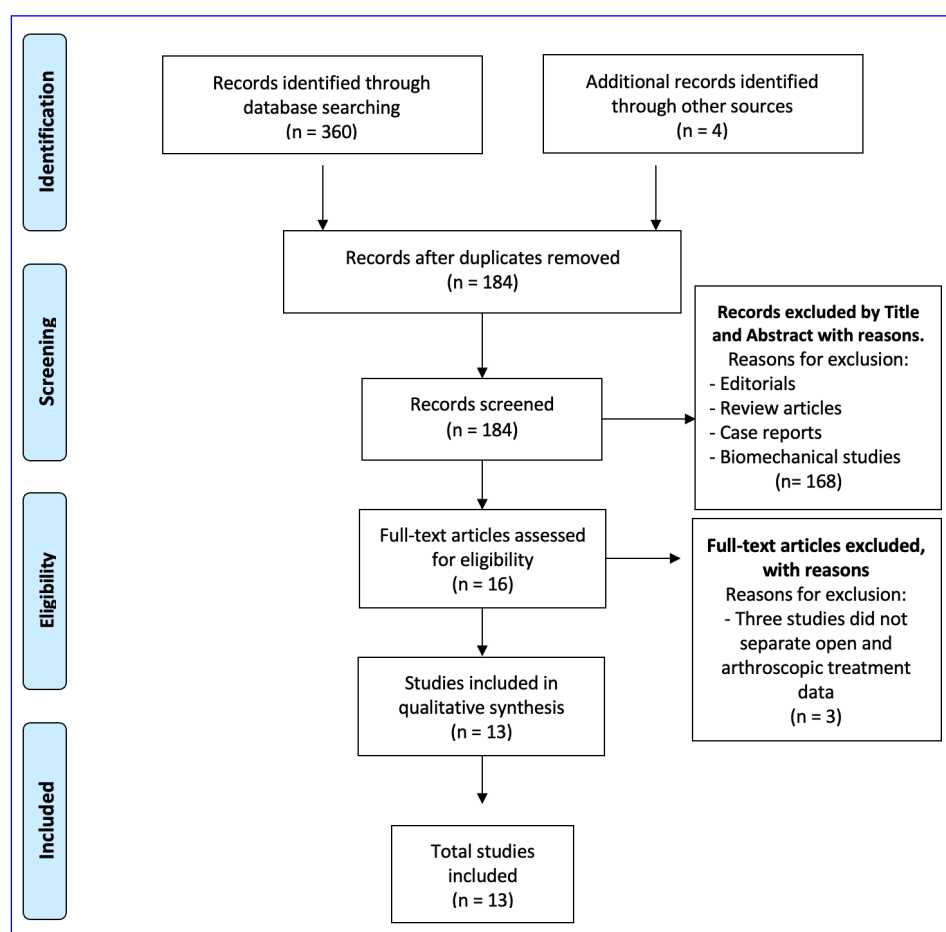


Figure 1. Prisma flow chart. n: number.

(HHS), Non-Arthritic Hip Score (NAHS), Visual Analogue Scale (VAS), Western Ontario and McMaster Universities Arthritis Index (WOMAC), Short Form-12 (SF12), International Hip Outcome Tool (iHOT12), Hip Disability and Osteoarthritis Outcome Score (HOOS), Hip Sports Activity Scale (HSAS), Hip Outcome Score Sport-Specific Subscale (HOS-SSS), Hip Outcome Score for Activities of Daily Living (HOOS-ADL), Japanese Orthopedic Association (JOA) score, EuroQoL-5 Dimension Questionnaire (EQ-5D), Hip-Related Quality of Life (QoL) score, and University of California Los Angeles (UCLA) activity score. Postoperative protocols, complications, and revision rates were also recorded. The structured template facilitated the organized and comprehensive analysis of the collected data.

Data Analysis

Data analyses were conducted using R software (2022 version 4.1.3, R Core Team, Vienna, Austria). Given the expected clinical and methodological heterogeneity, we prespecified a narrative synthesis and did not perform a meta-analysis. Continuous outcomes were extracted as means and standard deviations (SDs) for each study and are reported individually. There was no pooling of data across studies, imputation of variances, or transformation of medians/ranges. For event outcomes (such as recurrence, complications, and conversion to total hip arthroplasty), we present descriptive pooled proportions, calculated as the sum of events divided by the total number of hips among the studies reporting that endpoint. The 95% confidence intervals (CIs) were determined using the Wilson method; therefore, the denominators vary by endpoint.

RESULTS

Thirteen studies^{9-11,17-26} (LoE 4), published between 2008 and 2024, met all inclusion criteria and were included in the qualitative analysis. All were retrospective, except for those by Ferro et al²² and Polesello et al²⁵, which were prospective. A total of 369 patients were analyzed. Among the 12 studies reporting sex distribution, 198 were males and 150 females, with a mean patient age ranging from 26.7 to 45.1 years. Eight studies^{10,17,18,20,21,23-25} reported the side affected: 99 patients had left-sided involvement, and 139 had right-sided involvement. In eight studies^{9-11,17,18,21,23,24}, the mean time from symptom onset to surgery ranged from 2.5 to 52 months. Body mass index (BMI) or weight was reported in four studies^{9,10,18,19} (according to table 1, only 4 studies report BMI; please check) with values ranging from 23 to 24.6 kg/m².

Diagnosis

The diagnosis of hip SC was established based on medical history, physical examination, and imaging – namely anteroposterior and lateral radiographs, CT scans, arthrograms, or MRI. Eleven studies^{9,11,17-21,23-26} reported clinical symptoms such as hip pain, mechanical symptoms (limping, crepitus), and restricted ROM. Seven studies^{9,11,17,18,21,23,24} described the radiologic diagnostic modalities. Cartilage damage of the femoral head and acetabulum was classified using the Tönnis grading system in six studies^{9,17-19,22,24}, while Milgram's histological staging was reported in seven^{9,18,21,23-26}. Six studies^{9,17-19,22,24} also noted concomitant joint conditions. An overview of diagnostic features is provided in Table 1.

Surgical Technique

All patients underwent hip arthroscopy, with or without traction, for primary SC. Synovectomy and loose body removal techniques were described in sufficient detail to achieve the maximum Coleman score (Figure 2). Patients were positioned supine in all studies except Marchie et al¹¹, who used the lateral decubitus position. Twelve studies^{9-11,17-24,26} specified the arthroscopic portals used (anterolateral, mid-anterior, or posterolateral), and 11^{9-11,17-24} detailed the arthroscopic techniques. Four studies^{11,17,19,24} reported surgery durations ranging from 80 to 144 minutes (Table 2).

Postoperative Rehabilitation

Postoperative rehabilitation protocols are summarized in Table 2. Eight studies^{9,11,17,18,20,22,24,26} described rehabilitation programs and weight-bearing restrictions in detail. Follow-up periods across the 13 studies ranged from 17.1 to 104.9 months.

Table 1. Main demographic characteristics of patients collected in studies included in the systematic review.

Authors (year)	Study design (LoE)	No. of patients, N	Age, years, Mean±SD (range)	M/F, N/N	RT/LT, N/N	BMI, kg/m ² , Mean±SD (range)	Associated pathology, N (%)	Tönnis grading, N (%)	Milgram staging, N (%)	Symptoms, N (%)	Radiographic findings, N (%)	Symptomatic period; Mean±SD (range)
Zini et al ¹⁷ (2013)	Retrospective IV	11	34 (18-55)	6/5	5/6	/	Cam impingement: 2; Labral lesion: 1	Grade 0: 4 Grade 1: 4 Grade 2: 3	/	Hip pain: 11; Mechanical symptoms: 8; Limp: 4; Crepitus: 5; Restricted ROM: 7	X-ray: 8 (73%); MRI: 9 (82%)	38 (6-96)
Liu et al ²⁶ (2020)	Retrospective IV	21	/	/	/	/	/	/	Stage 0: 1 (4.8%) Stage 1: 11 (52.4%) Stage 2: 7 (33.3%) Stage 3: 2 (9.5%)	FADDIR test positive: 14; FABER test positive: 13	/	/
Lee et al ²⁴ (2012)	Retrospective IV	24	43 (32-63)	20/4	14/10	/	/	Grade 0: 10 (42%) Grade 1: 4 (17%) Grade 2: 8 (33%) Grade 3: 2 (8%)	Stage 0: 13 Stage 1: 8 Stage 2: 2 Stage 3: 1	Patrick test positive: 19; Impingement test positive: 15	X-ray: 20 (83%); MRI: 22 (92%)	24 (6-72)
Polesello et al ²⁵ (2015)	Prospective IV	5	45.1 (41-52)	1/4	5/0	/	/	/	Stage 2 and 3: 3 (50%)	Pain on 90° of flexion: 5 (100%); Pain going up and down stairs: 2 (33.3%)	/	/
Boyer and Dorfmann ²³ (2008)	Retrospective IV	111	43.3 (13-81)	54/57	63/48	/	/	/	Stage 1: 6 (5.4%) Stage 2: 47 (42.3%) Stage 3: 58 (52.3%)	Mechanical pain: 66 (93%); Intermittent pain: 74 (84%); Limited ROM: 57 (51.4%); Limp: 11 (9.9%)	Arthrography: 29 (26.1%); CT Arthrography: 44 (39.6%); MRI: 15 (13.5%); Radionuclide scanning: 6 (5.4%)	31 (6-60)

Table continued

Table 1. (Continued). Main demographic characteristics of patients collected in studies included in the systematic review.

Authors (year)	Study design (LoE)	No. of patients, N	Age, years, Mean±SD (range)	M/F, N/N	RT/LT, N/N	BMI, kg/m ² , Mean±SD (range)	Associated pathology, N (%)	Tönnis grading, N (%)	Milgram staging, N (%)	Symptoms, N (%)	Radiographic findings, N (%)	Symptomatic period; Mean±SD (range)
Ferro and Philippon ²² (2015)	Prospective IV	23	43.7 (24-58)	11/12	/	/	Chondral lesion-femur: 12 (57%); Chondral lesion-acetabulum: 18 (86%); Labral pathology: 21 (100%)	Grade 0: 14 (66.6%) Grade 1: 7 (28.5%) Grade 2: 1 (4%)	/	/	X-ray: 5 (23.8%) MRI: 14 (66.6%)	/
Zhang et al ¹⁰ (2021)	Retrospective IV	41	37.6 (14-69)	27/14	27/14	23.8 (18.8-31.4)	Labral lesions: 15 (36.6%); Cam impingement: 12 (29.2%); Pincer impingement: 2 (4.8%); Mixed Cam-Pincer impingement: 3 (7.3%)	/	/	/	X-ray: 19 (46.3%); CT scan: 24 (58.5%); MRI: 20 (48.8%)	30.6 (1-144)
Marchie et al ¹¹ (2011)	Retrospective IV	29	41 (26-66)	14/15	/	/	Labral lesion: 12 (41.4%)	/	/	Hip pain: 29 (100%); Mechanical symptoms: 18 (63%); Limp: 8 (28%); Restricted ROM: 17 (58%)	X-ray: 8 (28%); CT scan: 7 (24%); MRI: 21 (72%)	52 (4-120)
Wu et al ²⁰ (2024)	Retrospective IV	5	41 (28-54)	3/2	4/1	/	/	/	/	Dull hip pain, swelling, and restricted ROM: 5 (100%)	/	/
Bakr et al ²¹ (2024)	Retrospective IV	13	26.69±7.13	7/6	10/3	/	/	/	Stage 1: 4 (30.7%) Stage 2: 6 (46.2%) Stage 3: 3 (23.1%)	Groin pain 13 (100%), Limited ROM 13 (100%), Catching sensations 9 (69.2%)	/	2.47±1.01

Table continued

Table 1. (Continued). Main demographic characteristics of patients collected in studies included in the systematic review.

Authors (year)	Study design (LoE)	No. of patients, N	Age, years, Mean±SD (range)	M/F, N/N	RT/LT, N/N	BMI, kg/m ² , Mean±SD (range)	Associated pathology, N (%)	Tönnis grading, N (%)	Milgram staging, N (%)	Symptoms, N (%)	Radiographic findings, N (%)	Symptomatic period; Mean±SD (range)
Zhu et al ¹⁸ (2024)	Retrospective IV	28	37.2 (14-59)	19/9	11/17	24.1 (18.8-32.1)	Synovial hypertrophy: 28 (100%); Labral lesion: 12 (42.9%); Cam impingement: 8 (28.6%); Pincer impingement: 2 (7.1%)	Grade 0: 12 (42.9%) Grade 1: 16 (57.1%)	Stage 2: 16 (57.1%) Stage 3: 12 (42.9%)	/	X-ray: 14 (50%); CT: 23 (82.1%); MRI: 26 (92.9%)	41±33.1 (3-120)
Lee et al ¹⁹ (2018)	Retrospective IV	10	35.4 (21-58)	8/2	/	23 (18.3-25.9)	/	Grade 0: 4 Grade 1: 6	/	/	/	/
Zhu et al ⁹ (2024)	Retrospective IV	48	40.23±12.1 (19-64)	28/20	/	24.6±3.1 (17.9-32.9)	Cam impingement: 28 (58.3%); Pincer impingement: 12 (25%)	Grade 0: 19 (39.6%) Grade 1: 29 (60.4%)	Stage 2: 29 (39.6%) Stage 3: 19 (60.4%)	/	/	37.3±37.8 (6-180)

M: male; F: female; SD: standard deviation; N: number of evaluation cases; %: percentage; RT: right; LT: left; /: not reported; FU: follow up; BMI: body mass index; ROM: range of motion; FADDIR: Flexion – ADduction – Internal Rotation; FABER: Flexion – ABduction – External Rotation; LoE: level of evidence; CT: computed tomography; MRI: magnetic resonance imaging; mns: months.

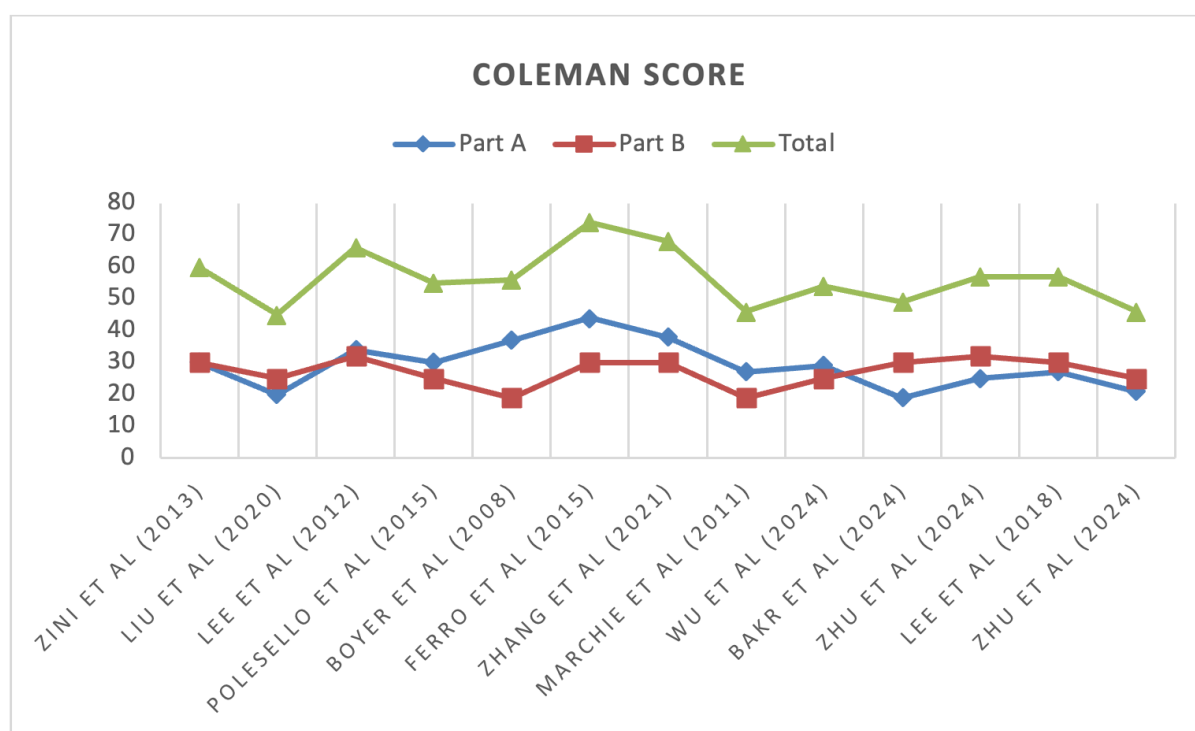


Figure 2. Retrospective studies analysis performed through the modified Coleman Methodology Score.

Final Reported Outcomes

Eleven studies^{9,10,17-22,24-26} reported subjective patient outcomes using scores such as mHHS, VAS, NAHS, iHOT12, HSAS, HOS-SSS, HOOS-ADL, JOA, EQ-5D, SF-12, Hip-Related QoL, and UCLA activity scores. A positive outcome was defined as full symptom resolution without residual synovitis or mobile loose bodies at final follow-up. Patient satisfaction ranged from 75% to 100% (Table 3).

Complications

Recurrence was summarized as a descriptive pooled proportion (events/hips) across studies that reported the endpoint, which was 22.8% (84/369; 95% CI, 18.8-27.3%). Conversion to total hip arthroplasty (THA) occurred in 7.3% (27/369; 95% CI 5.1-10.4%). These values are descriptive aggregates, not random-effects pooled estimates, and should be interpreted with consideration of between-study heterogeneity; per-study data are reported in Table 3. Major complications (Clavien-Dindo IIIb) included inadequate loose-body removal, which required revision (repeat arthroscopy, n=38; open revision, n=44). Three patients experienced transient neurological symptoms (perineal numbness, pedal paresthesia, or femoral nerve neuropraxia).

DISCUSSION

The most relevant finding of this systematic review is that arthroscopic treatment (AT) of hip SC achieves high patient satisfaction with low recurrence and complication rates.

As previously reported in the literature, SC predominantly affects males, with a male-to-female ratio of 1.3:1 – slightly lower than the 2:1 ratio typically reported for SC in all joints³. Patient age ranged from 13 to 81 years, with a prevalence in the third and fourth decades. These findings underscore the importance of early diagnosis and appropriate treatment to minimize recurrence and delay progression

Table 2. Surgical details and postoperative therapy of patients following arthroscopic treatment of hip chondromatosis.

Authors (year)	Surgical table position	Operative time, minutes, Mean \pm SD (range)	Surgical technique	Arthroscopic portals	Post-operative protocol	FU years, Mean \pm SD (Range)
Zini et al ¹⁷ (2013)	Supine	95 (72-147)	Larger fragments resected with burs or blades. Radiofrequency probes for synovectomy and reducing bleeding	Anterolateral, mid-anterior, posterolateral	WB as tolerated with crutches for 3 weeks. ROM and muscle tone with closed-chain joint stabilization and core strengthening exercises.	22 (12-36)
Liu et al ²⁶ (2020)	Supine	/	/	Distal anterolateral, anterolateral, anteromedial	Passive ROM was restricted up to 90°. In the first 4 weeks, WB as tolerated with crutches was allowed until full WB was reached.	/
Lee et al ²⁴ (2012)	Supine	113 (74-156)	Arthroscopic loose body removal with probe or grasper, and smaller loose bodies removed by lavage + synovectomy	Anterior, anterolateral, and posterolateral	Bed rest for 1 to 2 days after surgery. Partial WB started at 2 days and the patients were discharged at 3 to 5 days after surgery	41 (12-133)
Polesello et al ²⁵ (2015)	Supine	/	/	/	/	17.1 (8-25)
Boyer and Dorfmann ²³ (2008)	Supine	/	Loose bodies removed using probes and/or graspers, some loose bodies were crushed in situ and removed by lavage	Lateral, anterolateral and posterolateral portals,	/	78.6 (12-196)
Ferro and Philippon ²² (2015)	Supine	/	Loose bodies removed using shaver and grasper or washed. A thorough arthroscopic synovectomy	Anterolateral and mid-anterior	Partial WB for 3 weeks. Stationary bike first day after surgery.	30
Zhang et al ¹⁰ (2021)	Supine	/	Loose bodies removed by lavage, and larger ones removed by grasper	Anterolateral and mid-anterior	/	48.7 (27-119)
Marchie et al ¹¹ (2011)	lateral	80 (68-138)	Loose bodies removed by lavage, grasper with morcellization, and electrothermal device for loose bodies removal	Anterosuperior and posterolateral to the greater trochanter	Fully WB with crutches as tolerated on the same day of the surgical procedure.	64 (12-184)
Wu et al ²⁰ (2024)	Supine	/	Loose bodies removed by sing a probe or grasper, and smaller loose bodies could be removed by suction	Anterolateral and mid-anterior	Full ROM immediately after surgery. A passive ROM first restored, followed by an active range. Partial WB allowed 2nd day, and full WB allowed after 1 month.	25.2 (18-36)
Bakr et al ²¹ (2024)	Supine	/	Loose bodies removed by picking it up using grasper, or by saline wash	Proximal and distal antero-lateral portals	/	39 (18-60)

Table continued

Table 2 (Continued). Surgical details and postoperative therapy of patients following arthroscopic treatment of hip chondromatosis.

Authors (year)	Surgical table position	Operative time, minutes, Mean \pm SD (range)	Surgical technique	Arthroscopic portals	Post-operative protocol	FU years, Mean \pm SD (Range)
Bakr et al ²¹ (2024)	Supine	/	Loose bodies removed by picking it up using grasper, or by saline wash	Proximal and distal antero-lateral portals	/	39 (18-60)
Zhu et al ¹⁸ (2024)	Supine	/	Removal of loose bodies, and synovectomy	Proximal mid-anterior and mid-anterior	Passive ROM exercises were initiated on day 1. Partial WB exercises for restoring ROM from day 3 to week 3, followed by full WB walking at week 4.	104.9 (96-139)
Lee et al ¹⁹ (2018)	Supine	144 (75-185)	Arthroscopic loose body removal and synovectomy	Anterior, anterolateral, and posterolateral	/	45.6 (12-81.6)
Zhu et al ⁹ (2024)	Supine	/	Removal of loose bodies, and synovectomy	Proximal mid-anterior and mid-anterior	Passive ROM exercises were initiated on day 1 to 2 after surgery. Partial WB exercises for restoring ROM and promoting regular gait were introduced from day 3 to week 3, followed by full WB walking at week 4. Full WB muscle strength exercises and dynamic balance training began at week 6.	40.6 \pm 17.6 (24-100)

SD: standard deviation; WB: weight bearing; FU: follow-up; ROM: range of motion; /: not reported.

Table 3. Summary of pre- and post-operative outcomes, complications, recurrences, and revisions following arthroscopic treatment of hip chondromatosis.

Authors (year)	Pre-operative outcomes, Mean±SD (range)	Post-operative outcomes, Mea±SD (Range)	Satisfaction rate, N (%)	Recurrence, N/N	Complications N (%) ξ	Revision, N (%) ξ
Zini et al ¹⁷ (2013)	HHS: 59 (48-72)	HHS: 87 (55-100)	Very satisfactory: 3; Satisfactory: 5; Moderately satisfactory: 2	0	0 (0%)	0 (0%)
Liu et al ²⁶ (2020)	VAS: 5.9±0.9 mHHS: 36.4±7.1 iHOT12: 69.7±12.7	VAS: 2.2±1.1 mHHS: 85.9±18.1 iHOT12: 96.6±17.6	20 (95.2%)	/	/	/
Lee et al ²⁴ (2012)	VAS: 8.1±1.3 (5-10) HHS: 39±6.9 (22-65) UCLA: 3.2±2.7 (2-6)	VAS: 3.1±1.4 (0-6) HHS: 82±10.2 (43-100) UCLA: 8.5±2.5 (5-10)	18 (75%) good or excellent satisfactory	4	0 (0%)	4 (16.7%)
Polesello et al ²⁵ (2015)	mHHS: 54.1 (38.5-70.4) Facial Expressions Scale: 1.8 (1-3)	mHHS: 90.4 (79.1-95.7) Facial Expressions Scale: 5.1 (4-6)	(100%)	0	0 (0%)	0 (0%)
Boyer and Dorfmann ²³ (2008)	/	63 (56.7%) had excellent or good outcomes*	/	65/111	THR: 19 (17.1%); Synovectomy: 12 (10.8%); Open removal: 11 (9.9%)	A second arthroscopy was required: 23 (20.7%); An open surgery was required: 42 (37.8%)
Ferro and Philippon ²² (2015)	mHHS: 62±15 SF12 MCS: 56±10 SF12 PCS: 41.6±8 WOMAC: 27.1±17	mHHS: 84.8±12 SF12 MCS: 55.8±5 SF12 PCS: 53±8 WOMAC: 7.2±7	(95%)	2	THR: 2 (8.7 %)	A second arthroscopy was required, then THA was required: 1 (4.3%)
Zhang et al ¹⁰ (2021)	mHHS: 67±15.7 (32-87) HOOS-Symptoms: 78.8±16 (35-100) HOOS-Pain: 80.9±14.6 (30-97) HOOS-ADL: 84.5±15.6 (33.8-98) HOOS-Sport: 50.3±18.6 (6.3-81) HOOS-QoL: 62.2±17.8 (6.3-81) VAS: 3.9±1.2 (2-7)	mHHS: 83.7±13.0 (50-91) HOOS-Symptoms: 93.3±11.5 (60-100) HOOS-Pain: 93.6±10.8 (57.5-100) HOOS-ADL: 95±9.4 (67.6-100) HOOS-Sport: 80.6±26.8 (18.8-100) HOOS-QoL: 86.7±17.1 (50-100) VAS: 1.1±1.4 (0-5)	Excellent: 33 (80.5%) Good: 7 (17.0) Fair: 1 (2.4)	2	0 (0%)	2 (4.9%)
Marchie et al ¹¹ (2011)	/	11 (48%) had excellent or good outcomes*	/	7	Perineal numbness and pedal paresthesia: 2 (7%)	A second arthroscopic procedure: 5 (17.5%); Open arthrotomy: 2 (7%)
Wu et al ²⁰ (2024)	VAS: 3.2±0.8 (2-4) HHS: 58.6±12.7 (43-73)	VAS: 0.4±0.5 (0-1) HHS: 89.8±5.3 (81-95)	100%	1	0 (0%)	0 (0%)

Table continued

Table 3. (Continued). Summary of pre- and post-operative outcomes, complications, recurrences, and revisions following arthroscopic treatment of hip chondromatosis.

Authors (year)	Pre-operative outcomes, Mean±SD (range)	Post-operative outcomes, Mean±SD (Range)	Satisfaction rate, N (%)	Recurrence, N/N	Complications N (%) ξ	Revision, N (%) ξ
Bakr et al ²¹ (2024)	NAHS: 36.6±8.4 (21-48) mHHS: 37±6.3 (26-44)	NAHS: 62.38±11.23 (45-84) mHHS: 69.46±16.39 (35-84)	/	2	Femoral neurapraxia: 3 (23.1%); Osteoarthritis: 1 (7.7%)	2 (15.4%)
Zhu et al ¹⁸ (2024)	VAS: 3.8±1.2 mHHS: 66.4±14.4 NAHS: 45.2±16.2 iHOT-12: 48.4±15.6	VAS: 0.8±1.4 mHHS: 93.5±10.5 NAHS: 83.1±12.9 iHOT-12: 72.7±11.4	/	1	/	A second arthroscopy: 1 (3.6%)
Lee et al ¹⁹ (2018)	VAS: 5.4 (3-8) mHHS: 80.4 (67.0-92.4) UCLA: 4.4 (3-7) WOMAC: 24.2 (7-58)	VAS: 4 (3-5) mHHS: 90.1 (81.0-95.7) UCLA: 4.8 (3-7) WOMAC: 14.6 (0-24)	100%	0	0 (0%)	0 (0%)
Zhu et al ⁹ (2024)	VAS: 3.8±1.5 (1-7) mHHS: 65.8±12.7 (32-87) iHOT-12: 49.6±10.5 (23-74) NAHS: 46.9±7.2 (19-64)	VAS: 0.8±1.2 (0-4) mHHS: 93.5±6.7 (72-100) iHOT-12: 72.3±9.0 (49-83) NAHS: 81.7±8.6 (58-100)	/	0	0 (0%)	0 (0%)

N: number of evaluation cases; %: percentage; SD: standard deviation; mHHS: modified haris hip score; WOMAC: Western Ontario and McMaster Universities osteoarthritis index; iHOT-12: International Hip Outcome Tool; EQ-5D: EuroQoL-5 Dimension Questionnaire; VAS: visual analogue scale; NAHS: Non-Arthritic Hip Score; JOA: Japanese Orthopedic Association; iHOT-12: International Hip Outcome Tool; EQ-5D: EuroQoL-5 Dimension Questionnaire; SF-12: Short-Form 12; iHOT-12: International Hip Outcome Tool; HOOS: Hip Osteoarthritis Outcome Score; ADL: activities of daily living; QoL: Hip-Related Quality of Life; NAHS: non-arthritic hip score; UCLA: Activity Score University of California Los Angeles; /: not reported; THR: total hip replacement. *: data are expressed as the number of evaluation cases (percentage). ξ: Proportions in “Complications, N (%)” and “Revision, N (%)” are calculated as events/total hips among studies reporting that endpoint; 95% CIs (where shown in text) use the Wilson method. No random-effects pooling was performed.

to OA. Nevertheless, moderate to severe OA can negatively impact long-term outcomes of AT and must be carefully evaluated when planning treatment²⁷.

The most frequently reported symptoms at onset were groin pain and limited ROM, common to many hip pathologies, and thus potentially delaying diagnosis. The long symptom duration before surgery, ranging from 3 to 180 months, highlights this diagnostic challenge. Imaging plays a key role in differential diagnosis; since intra-articular loose bodies may not be visible on early radiographs, advanced imaging – preferably MRI – is essential for accurate diagnosis and surgical planning⁵.

Surgical treatment in early-stage SC generally provides satisfactory outcomes; however, proper patient selection and thorough assessment of joint status remain essential. Removal of loose bodies may offer symptomatic relief, but in cases of coexisting OA, hip preservation surgery may fail. THA remains the best option for advanced joint degeneration, ensuring long-term symptom resolution²⁸.

The debate between open surgery and AT continues. Surgical hip dislocation (SHD), as described by Ganz⁷, enables full access to the joint while preserving femoral head vascularity, thus reducing the risk of avascular necrosis. This approach allows comprehensive removal of loose bodies, evaluation of joint damage, and treatment of associated conditions such as labral tears or cam deformities. However, SHD is more invasive, carries a higher risk of soft tissue trauma, and may complicate future THA due to scar tissue formation.

Recent technical advancements and the availability of dedicated instruments have established hip arthroscopy as a valid alternative for SC management²⁹. While both approaches require specific expertise and present steep learning curves, AT offers the advantages of minimal invasiveness and faster recovery. Criticisms of AT include the potential for recurrence due to incomplete loose body removal, often limited by reduced joint visibility, and the theoretical risk of malignant lesion dissemination. Nevertheless, modern instrumentation and multiple arthroscopic portals now permit near-complete visualization of the joint, allowing meticulous removal of loose bodies and minimizing iatrogenic cartilage damage. Additionally, the risk of malignant transformation in SC is extremely low, and the likelihood of tumor spread after arthroscopic capsulotomy is negligible³⁰.

There is currently no universally accepted surgical technique. The approach must be tailored to the location and extent of the loose bodies and to patient positioning. While the supine position is more commonly used, the lateral position may offer the advantage of gravitational pooling of loose bodies toward the fovea, simplifying their identification and removal.

Most included studies had small sample sizes, reflecting the rarity of this disease. Boyer and Dorfmann²³ reported the largest cohort treated with AT for hip SC; however, this 2008 study includes patients operated on between 1985 and 2000. Limitations related to outdated imaging, lack of surgical standardization, and variable diagnostic accuracy may have contributed to the relatively poor outcomes observed in that cohort, including high recurrence and complication rates. With modern advancements, clinical results have improved, but there remains a need for protocols tailored to the disease stage.

In addition, case reports and technical notes, such as those by Rath et al³¹ and Carulli et al³², have described arthroscopic management of hip SC, further underscoring both the technical feasibility and the rarity of this condition. Although informative, these reports were not included in our systematic review due to their study design and limited follow-up, as per our predefined inclusion criteria.

Limitations

This review has several limitations. First, most of the included studies were retrospective, often with small sample sizes and heterogeneous populations in terms of age, symptom duration, disease severity, and concomitant pathologies. Given these sources of heterogeneity, we deliberately refrained from meta-analytic pooling of continuous outcomes and reported study-level results instead. Event outcomes (recurrence, complications, THA) were summarized as descriptive pooled proportions with 95% CIs, which provide an overall orientation but may over- or under-represent individual cohorts. This approach minimizes the risk of misleading precision while preserving transparency of the evidence base. Second, diagnostic strategies varied widely, with some patients being assessed only with radiographs and others undergoing CT or MRI scans. Third, surgical interventions were not standardized, with different combinations of loose body removal and synovectomy. Postoperative rehabilitation protocols also varied significantly according to surgeon preference and intraoperative findings, which may have influenced recovery. Finally, the follow-up duration

varied substantially (12-196 months), introducing potential bias and limiting the reliability of long-term outcome comparisons. A uniform clinical and radiological follow-up strategy would greatly enhance the comparability and validity of future data.

Further high-quality research is needed to evaluate the long-term efficacy, safety, and cost-effectiveness of arthroscopic management of hip SC. Large, well-designed randomized controlled trials with homogeneous control groups are essential to clarify the advantages of AT compared to open surgery. Moreover, improved patient stratification based on age, joint status, and disease stage is crucial for selecting the most appropriate treatment. Standardized diagnostic algorithms and postoperative rehabilitation protocols are also required to reduce diagnostic delays and optimize functional recovery.

CONCLUSIONS

This systematic review demonstrates that ATs represent a viable and effective treatment option for hip SC, particularly when performed by experienced hip arthroscopists. ATs offer high patient satisfaction, significant functional improvement, and acceptable recurrence rates, while maintaining the advantages of a minimally invasive approach. However, the considerable variability in diagnostic methods, surgical strategies, and postoperative protocols highlights the urgent need for standardized treatment guidelines. In cases of advanced joint degeneration, THA may remain the most appropriate therapeutic alternative.

CONFLICT OF INTEREST:

The authors declare that they have no conflict of interest.

FUNDING:

The authors received no funding for this research

AI DISCLOSURE:

The authors declare that artificial intelligence was not utilized to assist in any aspects of this manuscript's formulation.

AVAILABILITY OF DATA AND MATERIALS:

All data generated or analyzed during this study are included in this manuscript.

ETHICS APPROVAL AND INFORMED CONSENT:

Not applicable.

AUTHORS' CONTRIBUTIONS:

Riccardo Giai Via: substantial conception/design of work, performed measurements, data collection, statistical analysis, interpretation of data, drafting the work, critically revising the work, manuscript preparation, approving final version for publication, and agreement for accountability of all aspects of work.

Ahmed Elzeiny, Salvatore Pantè, Cristiano De Franco: substantial conception/design of work, interpretation of data for work, revising of the work for important intellectual content, final approval of the version for publication, and agreement to the accountability of all aspects of the work.

Kristijan Zoccola, Alessandro Massè: substantial conception/design of work, revising of the work for important intellectual content, final approval of the version for publication, and agreement to the accountability of all aspects of the work.

Fortunato Giustra, Francesco Bosco, Alessandro Aprato: revising of the work for important intellectual content, manuscript preparation, final approval of the version for publication, and agreement to accountability of all aspects of the work.

ORCID ID:

Riccardo Giai Via: 0000-0003-1170-230X

Ahmed Elzeiny: 0009-0000-9528-6723

Salvatore Pantè: 0000-0001-8203-2417

Cristiano De Franco: 0000-0003-1582-7345
 Fortunato Giustra: 0000-0001-6386-2933
 Francesco Bosco: 0000-0001-8306-1869
 Kristijan Zoccola: 0000-0003-4195-2879
 Alessandro Massè: 0000-0003-3999-4121
 Alessandro Aprato: 0000-0002-2514-4719

REFERENCES

1. Neumann JA, Garrigues GE, Brigman BE, Eward WC. Synovial Chondromatosis. *JBJS Rev* 2016; 4: e2.
2. van der Valk MR, Veltman ES, Assink J, Veen MR. Synovial chondromatosis of the hip, a case report and literature review. *J Orthop* 2019; 16: 249-253.
3. Adelani MA, Wupperman RM, Holt GE. Benign synovial disorders. *J Am Acad Orthop Surg* 2008; 16: 268-275.
4. McKenzie G, Raby N, Ritchie D. A pictorial review of primary synovial osteochondromatosis. *Eur Radiol* 2008; 18: 2662-2669.
5. Duif C, von Schulze Pellengahr C, Ali A. Primary synovial chondromatosis of the hip – is arthroscopy sufficient? A review of the literature and a case report. *Technol Health Care* 2014; 22: 667-675.
6. Schagemann JC, Hunold P, Russlies M, Mittelstaedt H. Synovial chondromatosis of the hip with atypical MRI morphology and mistakable clinical symptoms – a case report. *Acta Orthop* 2011; 82: 246-249.
7. Ganz R, Gill TJ, Gautier E, Ganz K, Krügel N, Berlemann U. Surgical dislocation of the adult hip a technique with full access to the femoral head and acetabulum without the risk of avascular necrosis. *J Bone Joint Surg Br* 2001; 83: 1119-1124.
8. Gaii Via R, Giachino M, Elzeiny A, Aprato A. Arthroscopic Management of Pigmented Villonodular Synovitis of the Hip: A Systematic Review. *J Clin Med* 2024; 13: 6446.
9. Zhu Y, Gao G, Luan S, Xu Y. Longitudinal Assessment of Clinical Outcomes After Arthroscopic Treatment for Hip Synovial Chondromatosis and the Effect of Residual Loose Bodies: Minimum 4-Year and 8-Year Follow-up. *Am J Sports Med* 2024; 52: 2306-2313.
10. Zhang X, Gao G, Wang J, Xu Y. Clinical Outcomes after Arthroscopic Treatment of Synovial Chondromatosis in the Hip. *Cartilage* 2021; 13: 1324S-1330S.
11. Marchie A, Panuncialman I, McCarthy JC. Efficacy of hip arthroscopy in the management of synovial chondromatosis. *Am J Sports Med* 2011; 39 Suppl: 126S-131S.
12. Page MJ, McKenzie JE, Bossuyt PM, Boutron I, Hoffmann TC, Mulrow CD, Shamseer L, Tetzlaff JM, Akl EA, Brennan SE, Chou R, Glanville J, Grimshaw JM, Hróbjartsson A, Lalu MM, Li T, Loder EW, Mayo-Wilson E, McDonald S, McGuinness LA, Stewart LA, Thomas J, Tricco AC, Welch VA, Whiting P, Moher D. The PRISMA 2020 statement: An updated guideline for reporting systematic reviews. *BMJ* 2021; 372: n71.
13. Burns PB, Rohrich RJ, Chung KC. The levels of evidence and their role in evidence-based medicine. *Plast Reconstr Surg* 2011; 128: 305-310.
14. Ramponi L, Yasui Y, Murawski CD, Ferkel RD, DiGiovanni CW, Kerkhoffs GMMJ, Calder JDF, Takao M, Vannini F, Choi WJ, Lee JW, Stone J, Kennedy JG. Lesion size is a predictor of clinical outcomes after bone marrow stimulation for osteochondral lesions of the talus: A systematic review. *Am J Sports Med* 2017; 45: 1698-1705.
15. Dindo D, Demartines N, Clavien PA. Classification of surgical complications: A new proposal with evaluation in a cohort of 6336 patients and results of a survey. *Ann Surg* 2004; 240: 205-213.
16. Sideri S, Papageorgiou SN, Eliades T. Registration in the international prospective register of systematic reviews (PROSPERO) of systematic review protocols was associated with increased review quality. *J Clin Epidemiol* 2018; 100: 103-110.
17. Zini R, Longo UG, de Benedetto M, Maffulli N, Denaro V. Arthroscopic management of primary synovial chondromatosis of the hip. *Arthroscopy* 2013; 29: 420-426.
18. Zhu Y, Zhang X, Wang J, Gao G, Xu Y. Revision hip arthroscopy for hip synovial chondromatosis is effective despite inferior postoperative clinical outcomes compared to patients undergoing primary hip arthroscopy: A matched control study with minimum 2-year follow-up. *J Orthop Surg* 2024; 19: 819.
19. Lee YK, Moon KH, Kim JW, Hwang JS, Ha YC, Koo KH. Remaining loose bodies after arthroscopic surgery including extensive capsulectomy for synovial chondromatosis of the hip. *Clin Orthop Surg* 2018; 10: 393-397.
20. Wu W, Liu M, Zhou C, Chen D, Zhang Q, He H, Zhang J. Efficacy of outside-in hip arthroscopy without traction in the treatment of hip synovial osteochondromatosis. *Orthop Surg* 2024; 16: 2862-2867.
21. Bakr HMA, Abdelkader SM, Metwally O. Is arthroscopic management of synovial chondromatosis of the hip enough? *J Arthrosc Jt Surg* 2024; 11: 144-148.
22. Ferro FP, Philippon MJ. Arthroscopy provides symptom relief and good functional outcomes in patients with hip synovial chondromatosis. *J Hip Preserv Surg* 2015; 2: 265-271.
23. Boyer T, Dorfmann H. Arthroscopy in primary synovial chondromatosis of the hip: Description and outcome of treatment. *J Bone Joint Surg Br* 2008; 90: 314-318.
24. Lee JB, Kang C, Lee CH, Kim PS, Hwang DS. Arthroscopic treatment of synovial chondromatosis of the hip. *Am J Sports Med* 2012; 40: 1412-1418.
25. Polesello GC, Ono NK, Honda EK, Guimaraes RP, Ricioli W Jr, Queiroz MC, Guimaraes SM. Arthroscopic treatment of synovial osteochondromatosis of the hip. *Rev Bras Ortop* 2015; 44: 320-323.
26. Liu Y, Li J, Ma N, He R, Zhao L. Arthroscopic treatment of synovial chondromatosis of hip joint. *J Orthop Surg Res* 2020; 15: 405.
27. Domb BG, Gui C, Lodhia P. How much arthritis is too much for hip arthroscopy: A systematic review. *Arthroscopy* 2015; 31: 520-529.

28. Learmonth ID, Young C, Rorabeck C. The operation of the century: Total hip replacement. *Lancet* 2007; 370: 1508-1519.
29. Colvin AC, Harrast J, Harner C. Trends in hip arthroscopy. *J Bone Joint Surg Am* 2012; 94: e23.
30. Krych AJ, Odland AN, Rose PS, Kasperbauer JL, Wenger DE, Van Wymelbeke DM, Levy BA. Oncologic conditions that simulate common sports injuries. *J Am Acad Orthop Surg* 2014; 22: 223-234.
31. Rath E, Amar E, Doron R, Matsuda DK. Hip arthroscopy for synovial chondromatosis: Tips and tricks. *Arthrosc Tech* 2014; 3: e709-e712.
32. Carulli C, Schiavo A, Rigon A, De Marchi W, Innocenti M, Meccariello L, Innocenti M. Rare and uncommon diseases of the hip: Arthroscopic treatment. *Med Glas (Zenica)* 2021; 18: 293-298.