



POST-OPERATIVE STABILITY VARIES WITH DIFFERENT LATERAL EXTRA-ARTICULAR TENODESIS TECHNIQUES IN PRIMARY ANTERIOR CRUCIATE LIGAMENT RECONSTRUCTION: A SYSTEMATIC REVIEW

E.S. MAMERI^{1,2,3}, G.R. JACKSON¹, B. KERZNER¹, J.J. CONDON¹, D. DE WALD¹,
Z.A. KHAN¹, D.J. KAPLAN¹, F. FAMILIARI⁴, A. RUSSO⁵, S. ALLAHABADI¹,
J. SUGRAÑES^{1,6}, D.M. KNAPIK⁷, R.F. LA PRADE⁸, N.N. VERMA¹, J. CHAHLA¹

• • •

¹Department of Orthopaedic Surgery, Rush University Medical Center, Chicago, Illinois, USA

²Instituto Brasil de Tecnologia da Saúde, Rio de Janeiro, Brazil

³Department of Orthopedics and Traumatology, Federal University of São Paulo, EPM-UNIFESP, São Paulo, Brazil

⁴Department of Orthopedic and Trauma Surgery, Magna Græcia University, Catanzaro, Italy

⁵Department of Orthopedic and Trauma Surgery, Kore University, Enna, Italy

⁶Department of Orthopaedic Surgery, Hospital de La Santa Creu I Sant Pau,
Universitat Autònoma de Barcelona, Barcelona, Spain

⁷Department of Orthopaedic Surgery, Washington University and Barnes-Jewish Orthopedic Center,
Chesterfield, Missouri, USA

⁸Twin Cities Orthopedics, Edina, Minnesota, USA

CORRESPONDING AUTHOR

Jorge Chahla, MD, Ph.D; e-mail: Jorge.chahla@rushortho.com

ABSTRACT – Objective: This study aimed to systematically review and compare the post-operative stability of lateral extra-articular tenodesis (LET) techniques based on fixation type in the setting of primary anterior cruciate ligament (ACL) reconstructions.

Materials and Methods: Scopus, PubMed, and EMBASE databases were queried from database inception through August 2022, using 2020 PRISMA guidelines. Level I to IV human clinical studies that evaluated patient-reported out-comes and post-operative stability following primary ACL reconstruction with a LET were included. Patients were divided into three groups based on the LET fixation technique: proximal bony fixation, distal bony fixation, and soft-tissue fixation. A methodological quality assessment of the included studies was performed using the Newcastle-Ottawa Scale and the National Institute of Health Quality Assessment.

Results: Twenty-nine studies (30 cohorts), consisting of 2,545 patients (mean age range: 11.2-48 years) were identified. Mean follow-up ranged from 12 to 294 months. Forty percent (n = 1,019) of patients underwent soft-tissue fixation, while 37.1% (n = 945) underwent proximal bony and 22.8% (n = 581) distal bony LET fixation, in combination with ACL reconstruction. A residual pivot-shift finding was more commonly reported following distal bony fixation relative to the proximal bony ($p = 0.037$) and soft-tissue ($p = 0.0002$) fixation, whereas no significant difference was observed between the proximal bony vs. soft-tissue fixation ($p = 0.081$). The residual objective anterior translation was greater following bony distal fixation when compared to proximal bony ($p = 0.036$) and



soft-tissue fixation ($p = 0.001$), while no difference was found between proximal bony vs. soft-tissue fixation ($p = 0.159$). A residual positive Lachman was less frequently reported following proximal bony fixation relative to distal bony ($p = 0.001$) and soft-tissue ($p = 0.028$) fixation groups, with no difference between distal bony vs. soft-tissue fixation ($p = 0.171$).

Conclusions: Proximal bony and soft tissue fixation techniques result in lower reported rates of residual anterior and rotational instability relative to distal bony fixation techniques.

KEYWORDS: Lateral extra-articular tenodesis, Anterior cruciate ligament, Lateral augmentation, Lemaire, Knee, Anter-olateral complex.

INTRODUCTION

Anterior cruciate ligament (ACL) surgery represents one of the most common orthopedic procedures globally, with an estimated incidence of over 200,000 ACL injuries occurring annually in the United States alone¹. The ever-growing body of research on the anatomy and on optimizing technical execution during ACL reconstruction has led to increasingly positive patient-reported outcomes and graft failure rates under 5%². However, in high-risk patients, mainly males under 18 years of age, failure rates following isolated ACL reconstruction have been reported to reach upwards of 28%³. Additional risk factors for failure include high-grade rotatory instability (based on pivot shift), meniscal insufficiency, participation in high-level contact or pivoting sports, genu recurvatum, increased posterior tibial slope, and the need for revision ACL reconstruction⁴⁻⁸.

To minimize the risk of graft failure following ACL reconstruction, especially in high-risk patients, the performance of a lateral extra-articular tenodesis (LET) as an augmentation during both primary and revision ACL reconstruction has been increasingly recognized^{6,9,10}. If on one side biomechanical studies¹¹⁻¹⁷ have demonstrated improved rotational and anterior-posterior stability, as well as a reduction in intra-articular graft strain following LET relative to isolated ACL reconstruction, on the other side there is evidence that utilization of LET in conjunction with ACL reconstruction may disturb lateral compartment contact mechanics and contribute to joint degeneration^{18,19}. Clinically, the addition of a LET has been reported to decrease graft failure rates, while improving return to sport rates²⁰⁻²³. A recent survey of members of the ACL Study Group reported that 83% of survey respondents believed there is an appropriate role for the use of a LET during primary ACL reconstructions¹.

Various LET techniques and fixation methods have been reported^{11,18,24-26} to re-establish normal knee kinematics. While bony fixation on the femur utilizing the modified-Lemaire²⁷ technique remains the most frequently studied technique²⁸, other techniques, with bony fixation on the tibia such as the modified-Ellison²⁹, or all soft-tissue fixation alone, such as the Coker-Arnold technique³⁰, have been analyzed^{27,29}. However, no consensus remains on the superiority of a particular approach based on postoperative outcomes. The purpose of this study was to systematically review and compare postoperative outcomes and stability following isolated ACL reconstruction with LET based on LET fixation type. The authors hypothesized there would be no significant differences in postoperative outcomes or reported rates of instability between LET fixation locations.

MATERIALS AND METHODS

Search Strategy and Eligibility

Using the 2020 Preferred Reporting Items for Systematic Review and Meta-Analysis (PRISMA)³¹ guidelines, a systematic review was performed. The literature search was conducted on August 24th, 2022, by two independent authors (initials blinded for peer review) using Scopus, PubMed, and EMBASE databases for Level I to IV human clinical studies reporting patient-reported outcomes, clinical stability (Lachman and pivot-shift tests), and objective laxity in patients following primary ACL reconstruction with LET. The following search strategy was used: ((((((lateral extra-articular tenodesis) OR (LET)) OR (lateral extra-articular procedure) OR (iliotibial band tenodesis)) OR (lateral augmentation procedures)) OR (lateral extra-articular plasty) OR (lateral extra sling)) AND (((anterior cruciate ligament) OR (ACL)) AND (reconstruction))). Inclusion criteria comprised articles in English or with English-language translation reporting patient-reported outcomes and clinical results following ACL reconstruction with LET. Articles

were excluded if they failed to report outcomes following ACL reconstruction with LET, patients undergoing isolated ACL reconstruction, ACL repair, studies comparing different techniques in which isolated LET subgroups were not reported independently of isolated ACL reconstruction groups, as well as case reports, biomechanical studies, animal studies, review articles, and technique articles.

Two independent authors (initials blinded for peer review) screened article titles, abstracts, and full text, initially consisting of 424 articles, of which 360 were excluded. 64 full-text articles were evaluated for eligibility (Figure 1). Following the full-text screening, 29 papers met the inclusion/exclusion criteria.

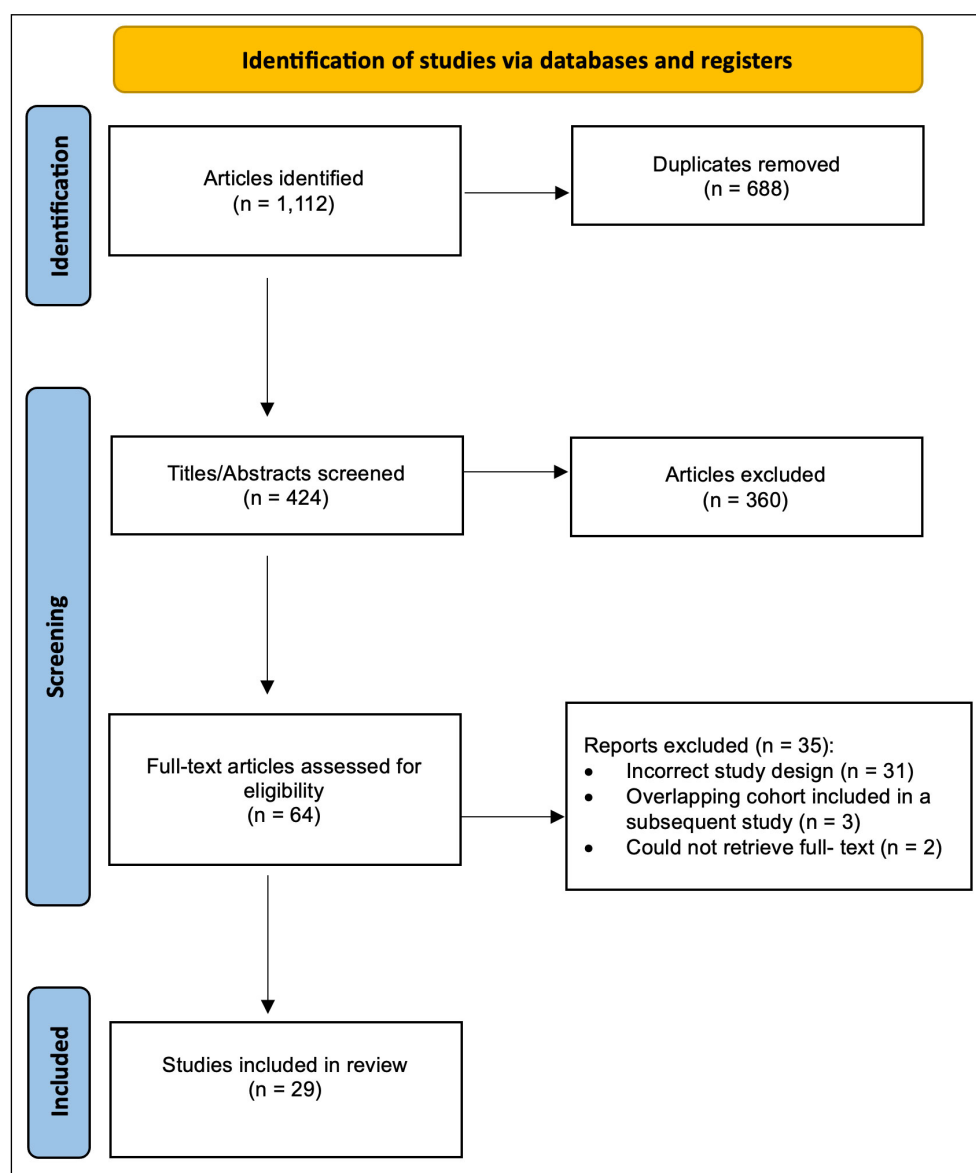


Figure 1. Preferred Reporting Items for Systematic Review and Meta-Analysis (PRISMA) flow diagram.

Data Extraction

The included studies were grouped based on surgical technique into one of three categories: (1) proximal bony fixation (Figure 2), (2) distal bony fixation (Figure 3), or (3) soft-tissue fixation (Figure 4). Data were collected using Microsoft Excel version 16.63 (Redmond, WA, USA). Collected variables included: article title, publication year, level of evidence (per Wright et al³²), patient demographics (age, sex), fixation technique (proximal bony, distal bony, soft tissue), patient-reported outcomes scores, return-to-sport (RTS) rate, and objective stability findings (Lachman, pivot-shift, and side-to-side difference

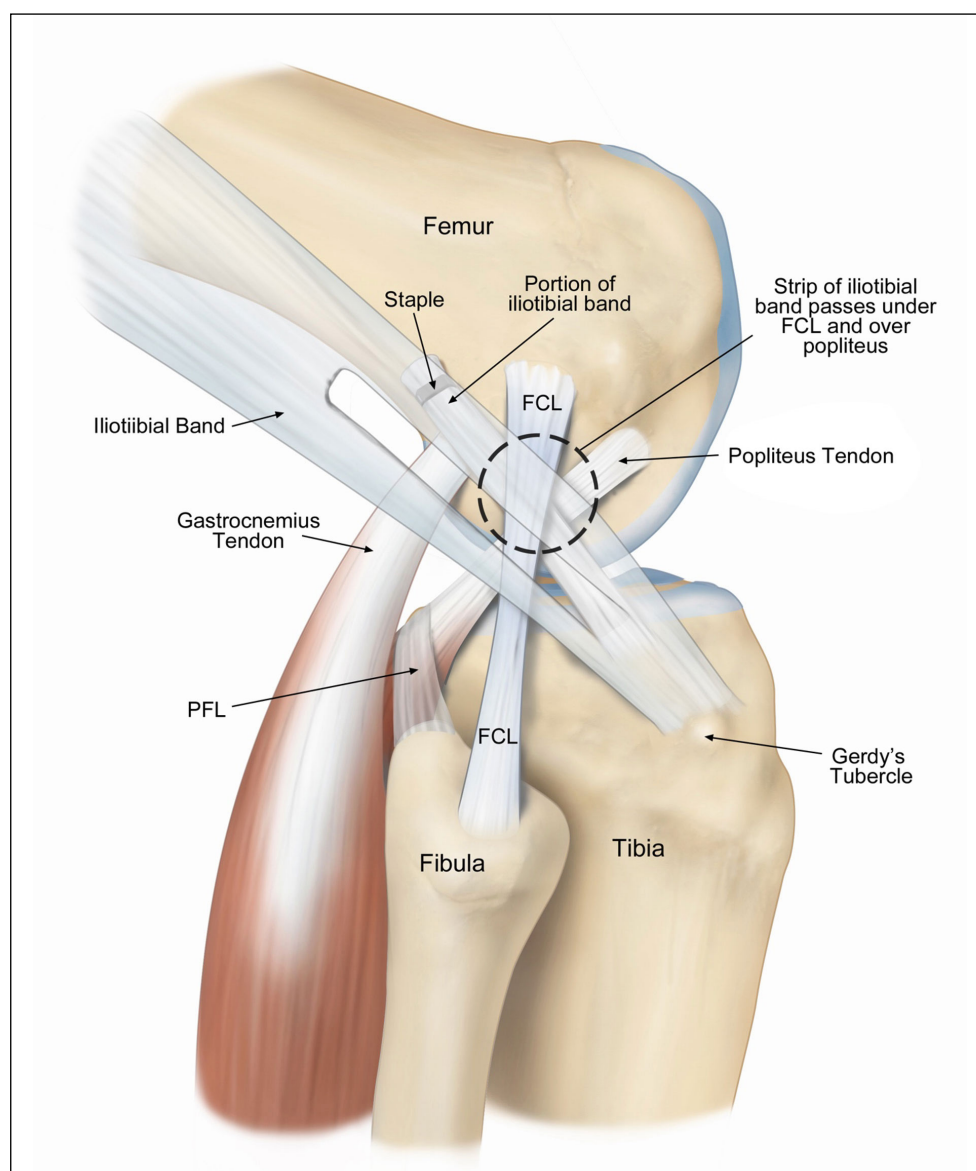


Figure 2. Illustration of the Andrews modified proximal bony lateral extra-articulate tenodesis⁶ fixation technique utilizing a staple (FCL, fibular collateral ligament; PFL, popliteofibular ligament).

(SSD) in anterior tibial translation) on physical examination. The proportions of patients across the total pooled sample with significant residual objective SSD in anterior tibial translation (> 3 mm), residual Lachman ($\geq 2+$), and residual pivot-shift ($\geq 1+$) were documented. Final follow-up time points were utilized during extraction and analysis.

Statistical Analysis

The primary outcome measures were those relevant to clinical stability, namely residual Lachman, residual pivot-shift, and objective side-to-side difference (SSD) in anterior tibial translation. Weighted proportions of unacceptable instability were calculated (binary random-effects model with DerSimonian Laird method) and outlined in forest plots (OpenMetaAnalyst, metafor R console package, Brown University, Providence, RI, USA) for visual depiction of the overall sample and subgroups based on fixation technique. To detect differences among the three subgroups, a Chi-square test was used; whenever a significant difference ($p < 0.05$) was observed, post-hoc Chi-square tests were used to determine exact group differences. Secondary outcomes included patient-reported outcomes and RTS rates, which were qualitatively compared.

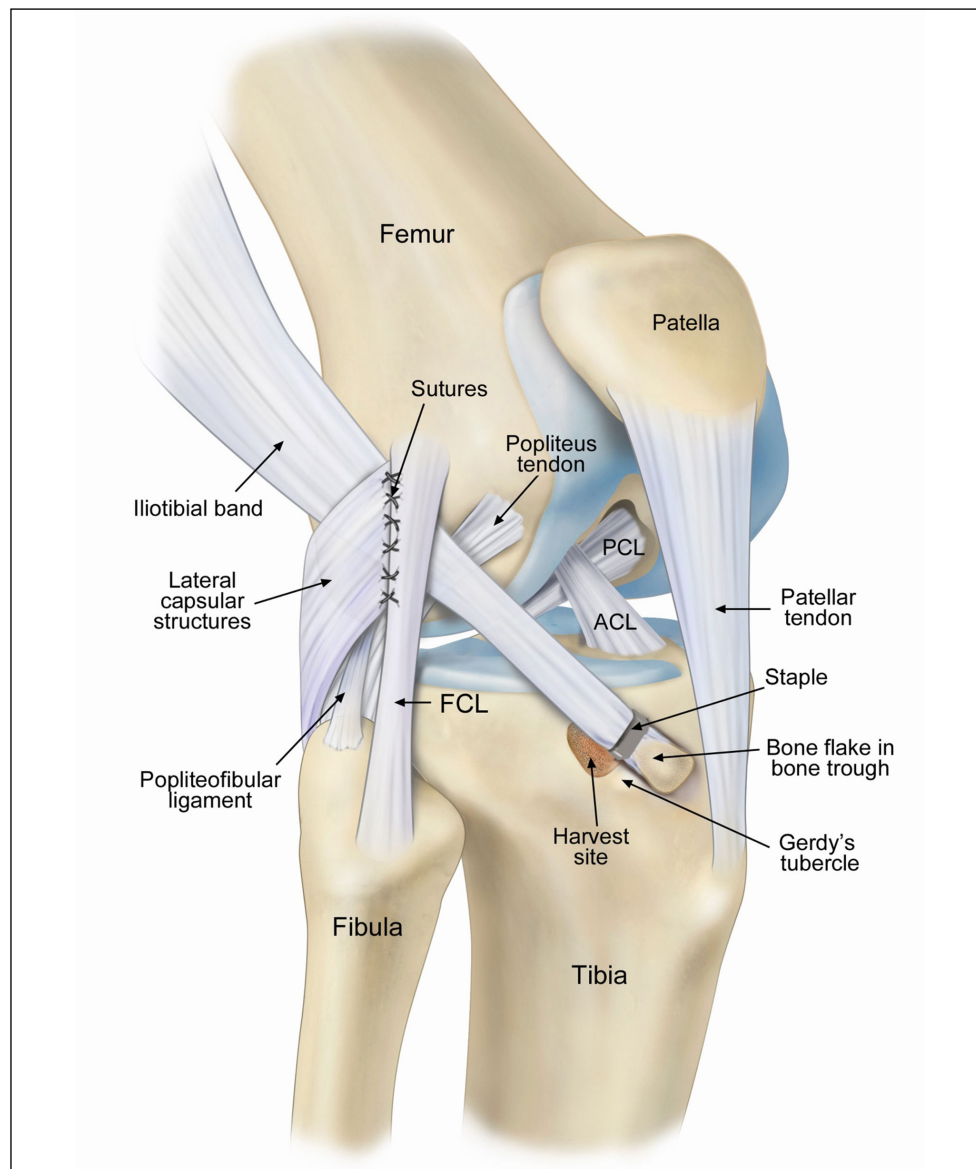


Figure 3. Illustration of the Ellison distal bony lateral extra-articular tenodesis fixation technique¹⁴ utilizing a staple (FCL, fibular collateral ligament; ACL, anterior cruciate ligament; PCL, posterior cruciate ligament).

Risk of Bias

In order to assess the risk of bias, two independent authors (initials blinded for peer-review) performed methodological quality assessments using the Newcastle-Ottawa Scale (NOS) for studies of level I-III evidence and the National Institute of Health (NIH) Quality Assessment for level IV evidence studies ([Supplementary Table 1](#) and [Supplementary Table 2](#)).

RESULTS

Twenty-nine studies (n=30 cohorts) with a pooled sample of 2,545 patients were identified. Three studies^{23,33,34} were of level evidence I (RCTs), one level II, 7 level III, and 18 were level IV ([Supplementary Table 3](#)). A total of 40% (n=1,019) underwent soft-tissue fixation, while 37.1% (n=945) were treated with proximal bony fixation and 22.8% (n=581) with distal bony fixation. Mean patient age ranged from 11.2 to 48 years, and mean follow-up time ranged from 12 to 294 months. Surgical technique aspects of each study, including graft type and width, along with fixation technique, are summarized in [Supplementary Table 3](#).

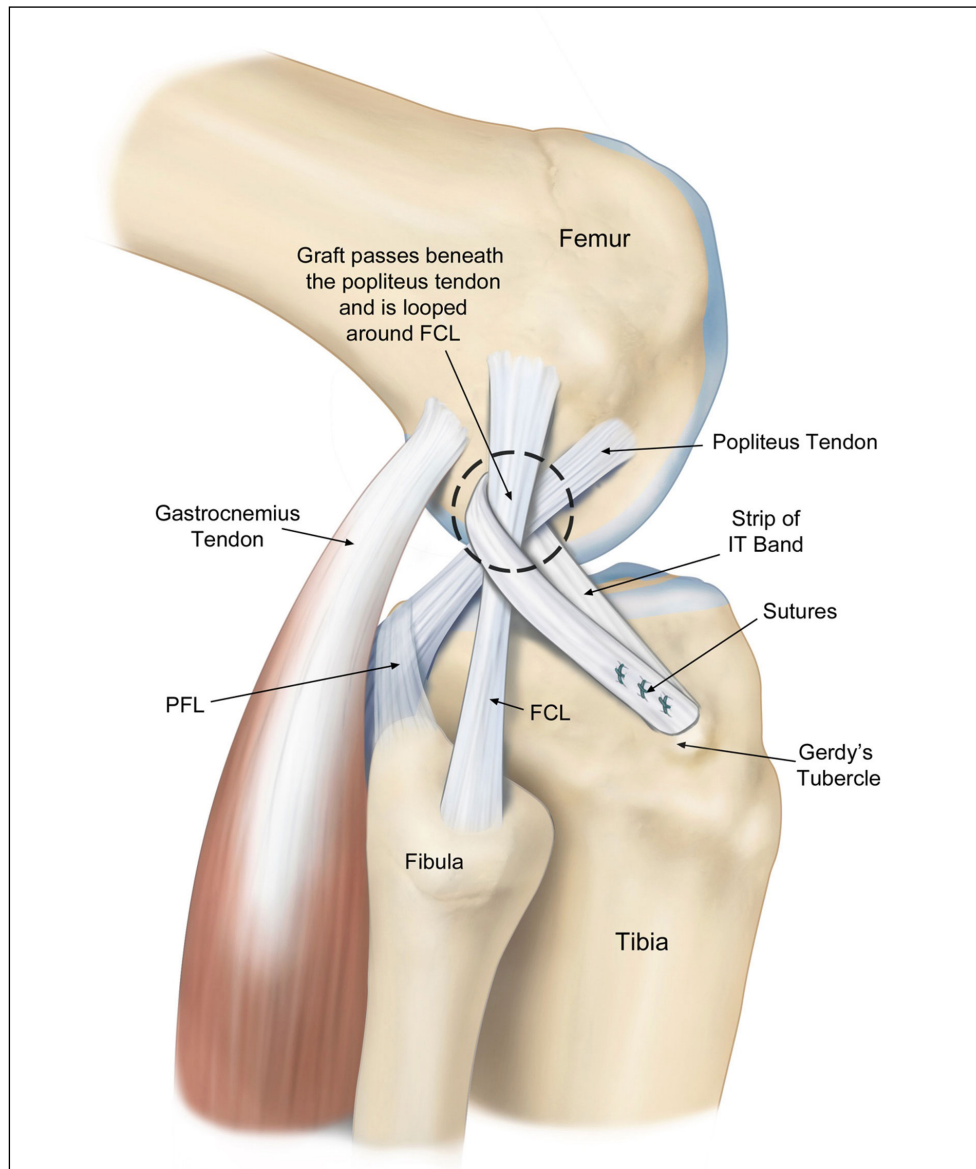


Figure 4. Illustration of the Arnold and Koker soft-tissue lateral extra-articular tenodesis fixation technique utilizing a suture-anchors (FCL, fibular collateral ligament; PFL, popliteofibular ligament; IT, iliotibial).

Residual Instability

The residual Lachman was significantly different between LET fixation groups ($\chi^2 = 10.69$; $p = 0.004$), with the reported Lachman positive in 17.5% ($n=13/74$ patients) of patients with distal bony fixation, in 5.5% ($n=13/236$ patients) following proximal bony fixation, and in 6.1% ($n=22/195$ patients) following soft-tissue fixation. Patients undergoing proximal bony fixation exhibited a significantly decreased rate of residual Lachman relative to distal ($\chi^2 = 10.66$; $p = 0.001$) and soft-tissue ($\chi^2 = 4.77$; $p = 0.028$) fixation groups, with no differences between distal bony and soft-tissue fixation ($\chi^2 = 1.87$; $p = 0.171$) (Figure 5).

A residual pivot-shift was significantly different between groups ($\chi^2 = 13.42$; $p = 0.001$), as identified in 16.5% ($n=76/459$ patients) of patients following proximal bony fixation, 22.9% ($n=57/248$ patients) following bony distal fixation, and 12.6% ($n=68/537$ patients) undergoing soft-tissue fixation. Subgroup differences revealed that patients undergoing distal bony fixation exhibited a significantly higher rate of residual pivot-shift laxity relative to the proximal bony ($\chi^2 = 4.35$; $p = 0.037$) and soft-tissue ($\chi^2 = 13.49$; $p = 0.0002$) fixation, with no differences between the proximal bony and soft-tissue fixation ($\chi^2 = 3.03$; $p = 0.081$) (Figure 6).

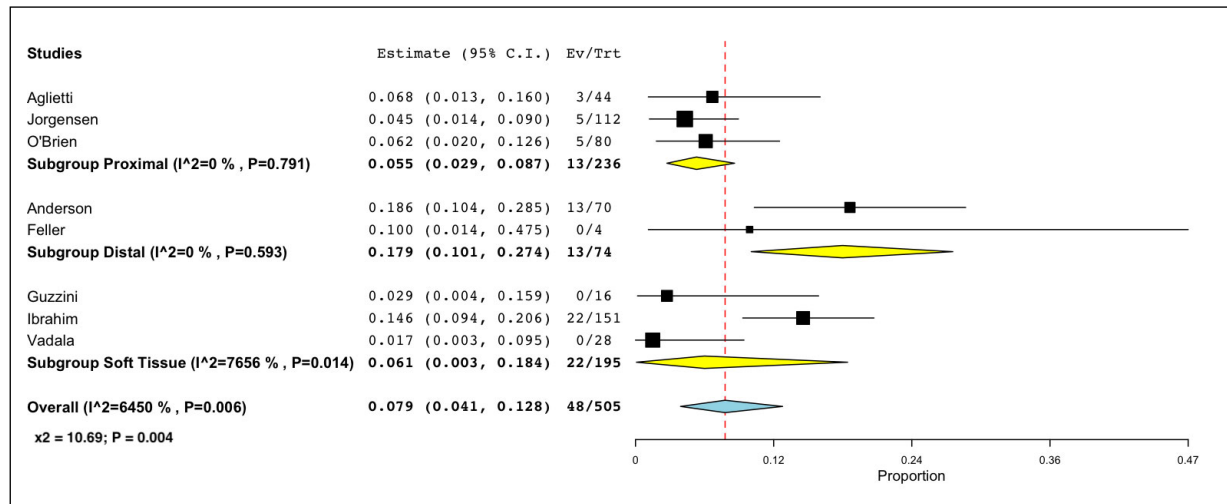


Figure 5. Forest plot comparing studies reporting a residual Lachman ($\geq 2+$).

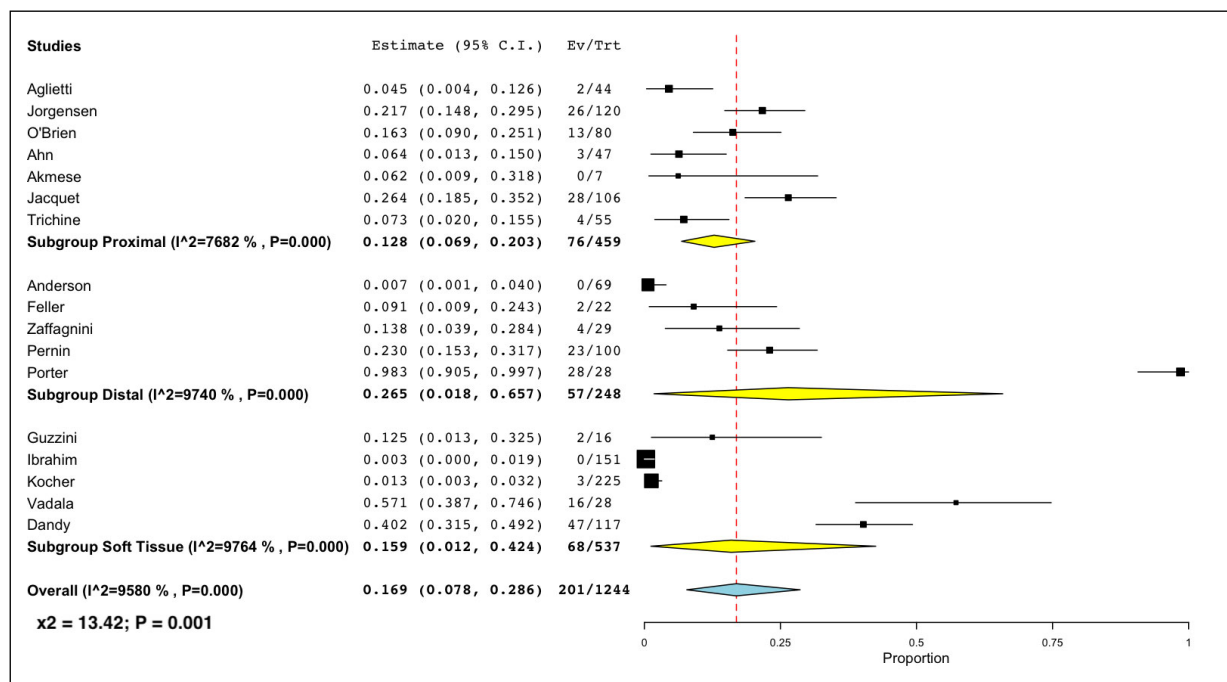


Figure 6. Forest plot comparing studies reporting a residual pivot-shift ($\geq 1+$).

Residual objective SSD in anterior tibial translation was significantly different between groups ($\chi^2 = 10.15$; $p = 0.006$), as identified in 22.5% ($n=46/204$ patients) of patients treated with proximal bony fixation, 33.3% ($n=38/114$ patients) were treated with distal bony fixation, and 16.3% ($n=22/135$ patients) with soft-tissue fixation. Subgroup differences revealed that patients undergoing distal bony fixation exhibited a significantly higher rate of residual SSD translation relative to the proximal bony ($\chi^2 = 4.37$; $p = 0.036$) and soft-tissue ($\chi^2 = 9.80$; $p = 0.001$) fixation, while no differences were observed between proximal bony and soft-tissue fixation ($\chi^2 = 1.98$; $p = 0.159$) (Figure 7).

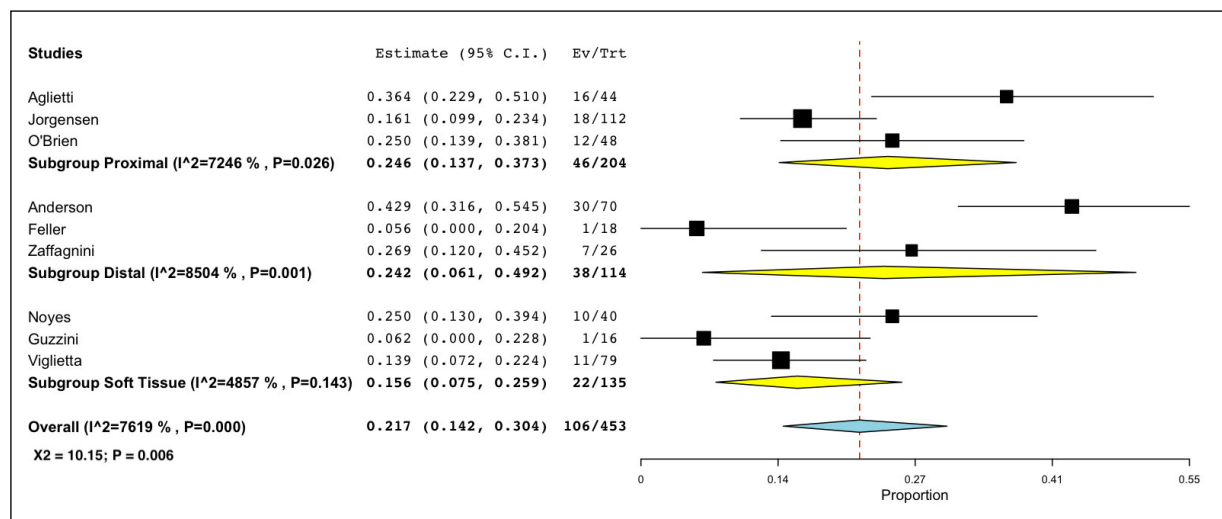


Figure 7. Forest plot comparing studies reporting residual objective anterior translation SSD (> 3 mm).

Patient-Reported Outcome Scores

Postoperative Lysholm scores were reported in 19 studies^{7,10,25,28,34-48} (n=20 cohorts) with a mean range from 87.8 to 99 in the proximal bony fixation group, 85.7 to 96.8 in the distal bony fixation group, and 84.2 to 96.8 in the soft-tissue fixation group. Postoperative International Knee Documentation Committee (IKDC) scores were reported in 17 studies^{7,10,26,28,33-36,38,42-45,49-52}, with a mean range from 78.4 to 93.3 following proximal bony fixation, 74.7-95 following distal bony fixation, and 78-96 following soft-tissue fixation ([Supplementary Table 4](#)).

Return to Sport

The mean RTS rate at the same level or higher level of play before injury was reported in 19 studies^{25,26,33,35,37-43,45-47,50,52-55}. RTS ranged from 55% to 91% following proximal bony fixation, 52.4-100% following distal bony fixation, and 66-100% in the soft-tissue fixation group.

DISCUSSION

The main findings of this systematic review were that in 29 studies, including 2,545 patients, soft tissue fixation was performed in 40% of patients, proximal bony fixation in 37.1%, and distal bony fixation in 22.8%. A positive post-operative Lachman test was less common in patients undergoing proximal bony fixation, while residual pivot-shift instability and SSD in anterior translation were more commonly reported following distal bony fixation. This information is valuable to surgeons planning LET fixation in the primary ACL reconstruction setting.

Multiple investigations have corroborated the improvement in rotatory stability and reduced risk of graft rupture when primary ACL reconstruction is combined with LET, especially in high-risk patients. A meta-analysis of seven RCTs conducted by Onggo et al²³ reported improved stability, better clinical outcomes, and a 3x less likely graft re-rupture rate in the LET group vs. the isolated ACL reconstruction group. Nevertheless, several studies^{20,56-58} compared the results of LET vs. anterolateral ligament (ALL) reconstructions and different ALL reconstruction techniques, while there is a paucity of studies that aim to investigate differences between LET techniques. To date, insufficient data allows for the superiority of fixing the LET construct to the femur, tibia, or soft-tissue alone, with no clinical study designs of direct comparison to our knowledge.

A previous review by Hurley et al⁵⁹ evaluated the effects of different lateral augmentation techniques relative to isolated ACL reconstructions. The authors observed that adding Lemaire or Cock-

er-Arnold LET techniques – of proximal and soft-tissue fixation, respectively – decreased graft re-ruptures and residual pivot-shift when compared to ACL reconstruction alone⁵⁹. Meanwhile, no benefit was found when the MacIntosh¹⁰ (proximal bony fixation), Losee⁶⁰ (distal bony fixation), or Marcacci⁴⁸ (soft-tissue fixation) techniques were used, which constituted one example each of a proximal, distal, or soft-tissue fixation⁵⁹. Our results are in agreement with the findings by Hurley et al⁵⁹, as we observed that the proximal bony fixation – mostly consisting of the modified-Lemaire technique – and the soft-tissue fixation group – mostly constituted of Coker-Arnold technique – exhibited superior post-operative anterior and rotational stability findings relative to distal bony fixation. While decreased residual Lachman was observed following proximal bony fixation relative to soft-tissue fixation, no difference was appreciated based on objective SSD, which is less prone to subjectivity and limited inter-observer reliability relative to physical examination tests. However, further investigations are warranted to determine if these observed differences are clinically relevant or associated with long-term improved outcomes. With a LET, there remains a potential for over-constraining the knee, which has been to increase the risk for the development of premature osteoarthritis^{16,17,28}. Meanwhile, Chiba et al²⁴ observed no effect of a LET on *in vivo* sagittal plane knee kinematics during a downhill running activity at 12 months post-operative – despite significantly reduced anterior translation during foot strike at 6 months.

RTS ranged from 55 to 100% in patients undergoing ACL reconstruction with a LET, with qualitatively similar RTS rates across techniques. In a similar fashion, no significant differences in RTS rates were reported in the network meta-analysis by Hurley et al⁵⁹. Further studies examining the impact of LET techniques on RTS rate and timing, based on athlete sex and activity level, are necessary in order to help better counsel patients and manage expectations following ACL reconstruction with LET.

Limitations

The present study had some limitations. First, the majority of the included studies were retrospective in nature and primarily of Level IV evidence, precluding formal meta-analysis of continuous variables such as patient-reported outcomes. Second, the wide range of reported RTS rates may be explained by a correspondingly wide range of mean follow-up time in our included studies. Additionally, notable heterogeneity was observed in terms of associated meniscal procedures; the posterior horn of the medial meniscus is a known secondary stabilizer of both anterior translation and rotation and could affect the assessed outcomes⁶¹. Differences in meniscal procedures could potentially influence between-group differences; however, it also may add external validity to the study, as it portrays the common need for addressing the meniscus in various manners during ACL reconstruction in clinical practice. Finally, as is the case in any systematic review, our search strategy and eligibility criteria might have unintentionally omitted data from relevant cohorts – albeit that risk was minimized by a thorough review of the reference list from each included study.

CONCLUSIONS

Proximal bony and soft tissue fixation techniques result in lower reported rates of residual anterior and rotational instability relative to distal bony fixation techniques. This information is valuable to surgeons planning LET fixation in the primary ACL reconstruction setting.

- What is known about the subject: Clinically, the addition of a LET has been reported to decrease graft failure rates, while improving return to sport rates. Various LET techniques and fixation methods have been reported, to re-establish normal knee kinematics. While bony fixation on the femur utilizing the modified-Lemaire technique remains the most frequently studied technique, other techniques, such as bony fixation on the tibia using the modified-Ellison, vs. all soft-tissue fixation alone, such as the Coker-Arnold technique, have been analyzed.

- What this study adds to existing knowledge: Soft tissue fixation was performed in 40% of patients, proximal bony fixation in 37.1%, and distal bony fixation in 22.8%. A positive post-operative Lachman test was less common in patients undergoing proximal bony fixation, while residual pivot-shift instability and SSD in anterior translation were more commonly reported following distal bony fixation. This information is valuable to surgeons planning LET fixation in the primary ACL reconstruction setting.

CONFLICT OF INTEREST:

Nothing to declare.

INFORMED CONSENT:

Not applicable.

ETHICS APPROVAL:

Not applicable.

FUNDING:

None.

ORCID ID:

Enzo S. Mameri: 0000-0001-9642-4868
 Garrett R. Jackson: 0000-0002-7018-8382
 Filippo Familiari: 0000-0002-3453-2043
 Arcangelo Russo: 0000-0002-3621-1761
 Sachin Allahabadi: 0000-0002-1185-3039
 Joan Sugrañes: 0000-0001-6209-1639
 Robert F. LaPrade: 0000-0002-9823-2306
 Nikhil N. Verma: 0000-0001-9875-2769
 Jorge Chahla: 0000-0002-9194-1150

DATA AVAILABILITY:

Data are available from the corresponding author.

REFERENCES

1. Sherman SL, Calcei J, Ray T, Magnussen RA, Musahl V, Kaeding CC, Clatworthy M, Bergfeld JA, Arnold MP. ACL Study Group presents the global trends in ACL reconstruction: biennial survey of the ACL Study Group. *J ISAKOS* 2021; 6: 322-328.
2. Kaeding CC, Pedroza AD, Reinke EK, Huston LJ, MOON Consortium; Spindler KP. Risk Factors and Predictors of Subsequent ACL Injury in Either Knee After ACL Reconstruction: Prospective Analysis of 2488 Primary ACL Reconstructions From the MOON Cohort. *Am J Sports Med* 2015; 43: 1583-1590.
3. Webster KE, Feller JA. Exploring the High Reinjury Rate in Younger Patients Undergoing Anterior Cruciate Ligament Reconstruction. *Am J Sports Med* 2016; 44: 2827-2832.
4. Bernhardtson AS, Aman ZS, Dornan GJ, Kemler BR, Storaci HW, Brady AW, Nakama GY, LaPrade RF. Tibial Slope and Its Effect on Force in Anterior Cruciate Ligament Grafts: Anterior Cruciate Ligament Force Increases Linearly as Posterior Tibial Slope Increases. *Am J Sports Med* 2019; 47: 296-302.
5. Firth AD, Bryant DM, Litchfield R, McCormack RG, Heard M, MacDonald PB, Spalding T, Verdonk PCM, Peterson D, Bardana D, Rezanoff A; STABILITY Study Group; Getgood AMJ, Willits K, Birmingham T, Hewison C, Wanlin S, Pinto R, Martindale A, O'Neill L, Jennings M, Daniluk M, Boyer D, Zomar M, Moon K, Moon R, Fan B, Mohan B, Buchko GM, Hiemstra LA, Kerslake S, Tynedal J, Stranges G, Mcrae S, Gullett L, Brown H, Legary A, Longo A, Christian M, Ferguson C, Mohtadi N, Barber R, Chan D, Campbell C, Garven A, Pulsifer K, Mayer M, Simunovic N, Duong A, Robinson D, Levy D, Skelly M, Shanmugaraj A, Howells F, Tough M, Thompson P, Metcalfe A, Asplin L, Dube A, Clarkson L, Brown J, Bolsover A, Bradshaw C, Belgrove L, Milan F, Turner S, Verdugo S, Lowe J, Dunne D, McGowan K, Suddens CM, Declercq G, Vuylsteke K, Van Haver M. Predictors of Graft Failure in Young Active Patients Undergoing Hamstring Autograft Anterior Cruciate Ligament Reconstruction With or Without a Lateral Extra-articular Tenodesis: The Stability Experience. *Am J Sports Med* 2022; 50: 384-395.
6. Getgood A. Editorial Commentary: Indications for Lateral Extra-Articular Tenodesis in Primary Anterior Cruciate Ligament Reconstruction. *Arthroscopy* 2022; 38: 125-127.
7. Mahmoud A, Torbey S, Honeywill C, Myers P. Lateral Extra-Articular Tenodesis Combined With Anterior Cruciate Ligament Reconstruction Is Effective in Knees With Additional Features of Lateral, Hyperextension, or Increased Rotational Laxity: A Matched Cohort Study. *Arthroscopy* 2022; 38: 119-124.
8. Sonnery-Cottet B, Saithna A, Cavalier M, Kajetanek C, Temponi EF, Daggett M, Helito CP, Thauinat M. Anterolateral Ligament Reconstruction Is Associated With Significantly Reduced ACL Graft Rupture Rates at a Minimum Follow-up of 2 Years: A Prospective Comparative Study of 502 Patients From the SANTI Study Group. *Am J Sports Med* 2017; 45: 1547-1557.
9. Geeslin AG, Chahla J, LaPrade RF. Combined Anterior Cruciate Ligament and Lateral Extra-Articular Reconstruction. *Arthroscopy* 2022; 38: 2600-2601.
10. Viglietta E, Ponzio A, Monaco E, Iorio R, Drogo P, Andreozzi V, Contedua F, Ferretti A. ACL Reconstruction Combined With the Arnold-Coker Modification of the MacIntosh Lateral Extra-articular Tenodesis: Long-term Clinical and Radiological Outcomes. *Am J Sports Med* 2022; 50: 404-414.
11. Delaloye JR, Hartog C, Blatter S, Schläppi M, Müller D, Denzler D, Murar J, Koch PP. Anterolateral Ligament Reconstruction and Modified Lemaire Lateral Extra-Articular Tenodesis Similarly Improve Knee Stability After Anterior Cruciate Ligament Reconstruction: A Biomechanical Study. *Arthroscopy* 2020; 36: 1942-1950.
12. Engebretsen L, Lew WD, Lewis JL, Hunter RE. The effect of an iliotibial tenodesis on intraarticular graft forces and knee joint motion. *Am J Sports Med* 1990; 18: 169-176.

13. Geeslin AG, Moatshe G, Chahla J, Kruckeberg BM, Muckenhirn KJ, Dornan GJ, Coggins A, Brady AW, Getgood AM, Godin JA, LaPrade RF. Anterolateral Knee Extra-articular Stabilizers: A Robotic Study Comparing Anterolateral Ligament Reconstruction and Modified Lemaire Lateral Extra-articular Tenodesis. *Am J Sports Med* 2018; 46: 607-616.
14. Godin JA, Chahla J, Moatshe G, Kruckeberg BM, Muckenhirn KJ, Vap AR, Geeslin AG, LaPrade RF. A Comprehensive Reanalysis of the Distal Iliotibial Band: Quantitative Anatomy, Radiographic Markers, and Biomechanical Properties. *Am J Sports Med* 2017; 45: 2595-2603.
15. Inderhaug E, Stephen JM, El-Daou H, Williams A, Amis AA. The Effects of Anterolateral Tenodesis on Tibiofemoral Contact Pressures and Kinematics. *Am J Sports Med* 2017; 45: 3081-3088.
16. Slette EL, Mikula JD, Schon JM, Marchetti DC, Kheir MM, Turnbull TL, LaPrade RF. Biomechanical Results of Lateral Extra-articular Tenodesis Procedures of the Knee: A Systematic Review. *Arthroscopy* 2016; 32: 2592-2611.
17. Xu J, Qiao Y, Han K, Xu C, Dong S, Zhao J. Modified Lemaire Lateral Extra-articular Tenodesis With the Iliotibial Band Strip Fixed on the Femoral Cortical Surface Reduces Laxity and Causes Less Overconstraint in the Anterolateral Lesioned Knee: A Biomechanical Study. *Arthroscopy* 2022; 38: 3162-3171.
18. Marom N, Jahandar H, Fraychineaud TJ, Zayyad ZA, Ouanezar H, Hurwit D, Zhu A, Wickiewicz TL, Pearle AD, Imhauser CW, Nawabi DH. Lateral Extra-articular Tenodesis Alters Lateral Compartment Contact Mechanics under Simulated Pivoting Maneuvers: An In Vitro Study. *Am J Sports Med* 2021; 49: 2898-2907.
19. Sheehan AJ, Lian J, Tisherman R, Meredith SJ, de Sa D, Lynch A, Lesniak BP, Musahl V. Augmentation of Anatomic Anterior Cruciate Ligament Reconstruction With Lateral Extra-articular Tenodesis Does Not Significantly Affect Rotatory Knee Laxity: A Time Zero, In Vivo Kinematic Analysis. *Am J Sports Med* 2020; 48: 3495-3502.
20. Helito CP, Sobrado MF, Moreira da Silva AG, Castro de Pádua VB, Guimarães TM, Bonadio MB, Pécora JR, Gobbi RG, Camanho GL. The Addition of Either an Anterolateral Ligament Reconstruction or an Iliotibial Band Tenodesis Is Associated With a Lower Failure Rate After Revision Anterior Cruciate Ligament Reconstruction: A Retrospective Comparative Trial. *Arthroscopy* 2023; 39: 308-319.
21. Hewison CE, Tran MN, Kaniki N, Remtulla A, Bryant D, Getgood AM. Lateral Extra-articular Tenodesis Reduces Rotational Laxity When Combined With Anterior Cruciate Ligament Reconstruction: A Systematic Review of the Literature. *Arthroscopy* 2015; 31: 2022-2034.
22. Keizer MNJ, Brouwer RW, de Graaff F, Hoogeslag RAG. Higher return to pre-injury type of sports after revision anterior ligament reconstruction with lateral extra-articular tenodesis compared to without lateral extra-articular tenodesis. *Knee Surg Sports Traumatol Arthrosc* 2023; 31: 1699-1703.
23. Onggo JR, Rasaratnam HK, Nambiar M, Onggo JD, Pai V, Damasena I, Riazi A, Babazadeh S. Anterior Cruciate Ligament Reconstruction Alone Versus With Lateral Extra-articular Tenodesis With Minimum 2-Year Follow-up: A Meta-analysis and Systematic Review of Randomized Controlled Trials. *Am J Sports Med* 2022; 50: 1137-1145.
24. Chiba D, Gale T, Nishida K, Suntaxi F, Lesniak BP, Fu FH, Anderst W, Musahl V. Lateral Extra-articular Tenodesis Contributes Little to Change In Vivo Kinematics After Anterior Cruciate Ligament Reconstruction: A Randomized Controlled Trial. *Am J Sports Med* 2021; 49: 1803-1812.
25. Dandy DJ, Gray AJ. Anterior cruciate ligament reconstruction with the Leeds-Keio prosthesis plus extra-articular tenodesis. Results after six years. *J Bone Joint Surg Br* 1994; 76: 193-197.
26. Getgood AMJ, Bryant DM, Litchfield R, Heard M, McCormack RG, Rezansoff A, Peterson D, Bardana D, MacDonald PB, Verdonk PCM, Spalding T; STABILITY Study Group; Willits K, Birmingham T, Hewison C, Wanlin S, Firth A, Pinto R, Martindale A, O'Neill L, Jennings M, Daniluk M, Boyer D, Zomar M, Moon K, Pritchett R, Payne K, Fan B, Mohan B, Buchko GM, Hiemstra LA, Kerslake S, Tynedal J, Stranges G, Mcrae S, Gullett L, Brown H, Legary A, Longo A, Christian M, Ferguson C, Mohtadi N, Barber R, Chan D, Campbell C, Garven A, Pulsifer K, Mayer M, Simunovic N, Duong A, Robinson D, Levy D, Skelly M, Shanmugaraj A, Howells F, Tough M, Spalding T, Thompson P, Metcalfe A, Asplin L, Dube A, Clarkson L, Brown J, Bolsover A, Bradshaw C, Belgrove L, Millan F, Turner S, Verdugo S, Lowe J, Dunne D, McGowan K, Suddens CM, Declercq G, Vuylsteke K, Van Haver M. Lateral Extra-articular Tenodesis Reduces Failure of Hamstring Tendon Autograft Anterior Cruciate Ligament Reconstruction: 2-Year Outcomes From the STABILITY Study Randomized Clinical Trial. *Am J Sports Med* 2020; 48: 285-297.
27. Jesani S, Getgood A. Modified Lemaire Lateral Extra-Articular Tenodesis Augmentation of Anterior Cruciate Ligament Reconstruction. *JBJS Essent Surg Tech* 2019; 9: e41.1-7.
28. Declercq J, Schuurmans M, Tack L, Verhelst C, Truijen J. Combined lateral extra-articular tenodesis and anterior cruciate ligament reconstruction: risk of osteoarthritis. *Eur J Orthop Surg Traumatol* 2023; 33: 1075-1082.
29. Al'Khafaji I, Devitt BM, Feller JA. The Modified Ellison Technique: A Distally Fixed Iliotibial Band Transfer for Lateral Extra-articular Augmentation of the Knee. *Arthrosc Tech* 2022; 11: e257-e262.
30. Arnold JA, Coker TP, Heaton LM, Park JP, Harris WD. Natural history of anterior cruciate tears. *Am J Sports Med* 1979; 7: 305-313.
31. Page MJ, McKenzie JE, Bossuyt PM, Boutron I, Hoffmann TC, Mulrow CD, Shamseer L, Tetzlaff JM, Akl EA, Brennan SE, Chou R, Glanville J, Grimshaw JM, Hróbjartsson A, Lalu MM, Li T, Loder EW, Mayo-Wilson E, McDonald S, McGuinness LA, Stewart LA, Thomas J, Tricco AC, Welch VA, Whiting P, Moher D. The PRISMA 2020 statement: an updated guideline for reporting systematic reviews. *Rev Esp Cardiol (Engl Ed)* 2021; 74: 790-799.
32. Wright JG, Swiontkowski MF, Heckman JD. Introducing levels of evidence to the journal. *J Bone Joint Surg Am* 2003; 85: 1-3.
33. Trichine F, Alsaati M, Chouteau J, Moya B, Bouzitouna M, Maza R. Patellar tendon autograft reconstruction of the anterior cruciate ligament with and without lateral plasty in advanced-stage chronic laxity. A clinical, prospective, randomized, single-blind study using passive dynamic X-rays. *Knee* 2014; 21: 58-65.
34. Vadalà AP, Iorio R, De Carli A, Bonifazi A, Iorio C, Gatti A, Rossi C, Ferretti A. An extra-articular procedure improves the clinical outcome in anterior cruciate ligament reconstruction with hamstrings in female athletes. *Int Orthop* 2013; 37: 187-192.
35. Akmes R, Ovali SA, Celebi MM, Malatyali B, Kocaoglu H. A Surgical Algorithm According to Pivot-Shift Grade in Patients With ACL Injury: A Prospective Clinical and Radiological Evaluation. *Orthop J Sports Med* 2021; 9: 23259671211025494.
36. Ferretti A, Monaco E, Giannetti S, Caperna L, Luzon D, Contedua F. A medium to long-term follow-up of ACL reconstruction using double gracilis and semitendinosus grafts. *Knee Surg Sports Traumatol Arthrosc* 2011; 19: 473-478.
37. Grassi A, Macchiarella L, Lucidi GA, Silvestri A, Dal Fabbro G, Marcacci M, Zaffagnini S. Ten-Year Survivorship, Patient-Reported Outcome Measures, and Patient Acceptable Symptom State After Over-the-Top Hamstring Anterior Cruciate Ligament Reconstruction With a Lateral Extra-articular Reconstruction: Analysis of 267 Consecutive Cases. *Am J Sports Med* 2021; 49: 374-383.

38. Guzzini M, Mazza D, Fabbri M, Lanzetti R, Redler A, Iorio C, Monaco E, Ferretti A. Extra-articular tenodesis combined with an anterior cruciate ligament reconstruction in acute anterior cruciate ligament tear in elite female football players. *Int Orthop* 2016; 40: 2091-2096.
39. Ibrahim SAR. Anterior Cruciate Ligament Reconstruction by Combined Intra-Articular (K. Lambert) and Extra-Articular Iliotibial Band Tenodesis (MacIntosh; Autologous Grafts). *Medical Principles and Practice* 1999; 8: 1-5.
40. Jacquet C, Pioger C, Seil R, Khakha R, Parratte S, Steltzlen C, Argenson JN, Pujol N, Ollivier M. Incidence and Risk Factors for Residual High-Grade Pivot Shift After ACL Reconstruction With or Without a Lateral Extra-articular Tenodesis. *Orthop J Sports Med* 2021; 9: 23259671211003590.
41. Jørgensen U, Bak K, Ekstrand J, Scavenius M. Reconstruction of the anterior cruciate ligament with the iliotibial band autograft in patients with chronic knee instability. *Knee Surg Sports Traumatol Arthrosc* 2001; 9: 137-145.
42. Kocher MS, Heyworth BE, Fabricant PD, Tepolt FA, Micheli LJ. Outcomes of Physeal-Sparing ACL Reconstruction with Iliotibial Band Autograft in Skeletally Immature Prepubescent Children. *J Bone Joint Surg Am* 2018; 100: 1087-1094.
43. Lanzetti RM, Pace V, Ciompi A, Perugia D, Spoliti M, Falez F, Auro C. Over the top anterior cruciate ligament reconstruction in patients with open physes: a long-term follow-up study. *Int Orthop* 2020; 44: 771-778.
44. Porter M, Shadbolt B. Modified Iliotibial Band Tenodesis Is Indicated to Correct Intraoperative Residual Pivot Shift After Anterior Cruciate Ligament Reconstruction Using an Autologous Hamstring Tendon Graft: A Prospective Randomized Controlled Trial. *Am J Sports Med* 2020; 48: 1069-1077.
45. Rackemann S, Robinson A, Dandy DJ. Reconstruction of the anterior cruciate ligament with an intra-articular patellar tendon graft and an extra-articular tenodesis. Results after six years. *J Bone Joint Surg Br* 1991; 73: 368-373.
46. Roberti di Sarsina T, Macchiarola L, Signorelli C, Grassi A, Raggi F, Marcheggiani Muccioli GM, Zaffagnini S. Anterior cruciate ligament reconstruction with an all-epiphyseal "over-the-top" technique is safe and shows low rate of failure in skeletally immature athletes. *Knee Surg Sports Traumatol Arthrosc* 2019; 27: 498-506.
47. Rowan FE, Huq SS, Haddad FS. Lateral extra-articular tenodesis with ACL reconstruction demonstrates better patient-reported outcomes compared to ACL reconstruction alone at 2 years minimum follow-up. *Arch Orthop Trauma Surg* 2019; 139: 1425-1433.
48. Zaffagnini S, Marcheggiani Muccioli GM, Grassi A, Roberti di Sarsina T, Raggi F, Signorelli C, Urrizola F, Spinnato P, Rimondi E, Marcacci M. Over-the-top ACL Reconstruction Plus Extra-articular Lateral Tenodesis With Hamstring Tendon Grafts: Prospective Evaluation With 20-Year Minimum Follow-up. *Am J Sports Med* 2017; 45: 3233-3242.
49. Ahn JH, Kim J, Mun JW. A Retrospective Comparison of Single-Bundle Anterior Cruciate Ligament Reconstruction With Lateral Extra-Articular Tenodesis With Double-Bundle Anterior Cruciate Ligament Reconstruction. *Arthroscopy* 2021; 37: 976-984.
50. Feller JA, Devitt BM, Webster KE, Klemm HJ. Augmentation of Primary ACL Reconstruction With a Modified Ellison Lateral Extra-articular Tenodesis in High-Risk Patients: A Pilot Study. *Orthop J Sports Med* 2021; 9: 23259671211021351.
51. Pernin J, Verdonk P, Si Selmi TA, Massin P, Neyret P. Long-term follow-up of 24.5 years after intra-articular anterior cruciate ligament reconstruction with lateral extra-articular augmentation. *Am J Sports Med* 2010; 38: 1094-1102.
52. Wilson PL, Wyatt CW, Wagner KJ 3rd, Boes N, Sabatino MJ, Ellis HB Jr. Combined Transphyseal and Lateral Extra-articular Pediatric Anterior Cruciate Ligament Reconstruction: A Novel Technique to Reduce ACL Reinjury While Allowing for Growth. *Am J Sports Med* 2019; 47: 3356-3364.
53. Aglietti P, Buzzi R, D'Andria S, Zaccherotti G. Long-term study of anterior cruciate ligament reconstruction for chronic instability using the central one-third patellar tendon and a lateral extraarticular tenodesis. *Am J Sports Med* 1992; 20: 38-45.
54. Noyes FR, Barber SD. The effect of an extra-articular procedure on allograft reconstructions for chronic ruptures of the anterior cruciate ligament. *J Bone Joint Surg Am* 1991; 73: 882-892.
55. O'Brien SJ, Warren RF, Pavlov H, Panariello R, Wickiewicz TL. Reconstruction of the chronically insufficient anterior cruciate ligament with the central third of the patellar ligament. *J Bone Joint Surg Am* 1991; 73: 278-286.
56. DePhillipo NN, Cinque ME, Chahla J, Geeslin AG, LaPrade RF. Anterolateral Ligament Reconstruction Techniques, Biomechanics, and Clinical Outcomes: A Systematic Review. *Arthroscopy* 2017; 33: 1575-1583.
57. Rayes J, Ouanezar H, Haidar IM, Ngbilo C, Fradin T, Vieira TD, Freychet B, Sonnery-Cottet B. Revision Anterior Cruciate Ligament Reconstruction Using Bone-Patellar Tendon-Bone Graft Combined With Modified Lemaire Technique Versus Hamstring Graft Combined With Anterolateral Ligament Reconstruction: A Clinical Comparative Matched Study With a Mean . *Am J Sports Med* 2022; 50: 395-403.
58. Xu J, Han K, Lee TQ, Xu C, Su W, Chen J, Yu J, Dong S, Zhao J. Anterolateral Structure Reconstruction Similarly Improves the Stability and Causes Less Overconstraint in Anterior Cruciate Ligament-Reconstructed Knees Compared With Modified Lemaire Lateral Extra-articular Tenodesis: A Biomechanical Study. *Arthroscopy* 2022; 38: 911-924.
59. Hurley ET, Bloom DA, Hoberman A, Anil U, Gonzalez-Lomas G, Strauss EJ, Alaia MJ. There are differences in knee stability based on lateral extra-articular augmentation technique alongside anterior cruciate ligament reconstruction. *Knee Surg Sports Traumatol Arthrosc* 2021; 29: 3854-3863.
60. Anderson AF, Snyder RB, Lipscomb AB. Anterior cruciate ligament reconstruction using the semitendinosus and gracilis tendons augmented by the Losee iliotibial band tenodesis. A long-term study. *Am J Sports Med* 1994; 22: 620-626.
61. Mameri ES, Dasari SP, Fortier LM, Verdejo FG, Gursoy S, Yanke AB, Chahla J. Review of Meniscus Anatomy and Biomechanics. *Curr Rev Musculoskelet Med* 2022; 15: 323-335.