



MEDIAL PATELLOFEMORAL LIGAMENT SURGERY IN THE PEDIATRIC POPULATION: A LITERATURE REVIEW ON THE CURRENT STATE OF THE ART

F. UBOLDI¹, A. PIERONI¹, F. PUGLIA¹, P. FERRU^{2,3},
D. PRIANO¹, A. MEMEO¹

• • •

¹Ortopedia Traumatologia Pediatrica, ASST Centro Specialistico Ortopedico Traumatologico Gaetano Pini-CTO, Milan, Italy

²Laboratory of Applied Biomechanics, Department of Biomedical Sciences for Health, Università degli Studi di Milano, Milan, Italy

³¹ Clinica Ortopedica, ASST Centro Specialistico Ortopedico Traumatologico Gaetano Pini-CTO, Milan, Italy

CORRESPONDING AUTHOR

Arianna Pieroni, MD; e-mail: arianna.pieroni@unimi.it

ABSTRACT – Objective: Patellofemoral instability typically manifests in pediatric patients between 10 to 16 years of age. This condition calls for surgical intervention, particularly after recurrent dislocations. Despite the variety of surgical approaches described for medial patellofemoral ligament (MPFL) reconstruction, consensus on the best graft type or technique for skeletally immature patients remains elusive. This review evaluates the efficacy of MPFL reconstruction in the pediatric demographic and explores whether the choice of graft and fixation technique affects the clinical outcomes, focusing on the best timing of the surgical procedure and possible additional procedures (e.g., medial tuberosity transposition).

Materials and Methods: This review was conducted by searching various digital databases, including PubMed, Medline, EMBASE, and Google Scholar, for articles published up to October 2023. Studies were included if they discussed techniques and outcomes of MPFL surgery in the pediatric population. Exclusion criteria encompassed non-English language articles, articles that lacked specific data on MPFL surgery techniques and outcomes, or those not addressing MPFL surgery in pediatric patients. Three independent authors (one resident and two researchers) reviewed each article for inclusion. In cases of disagreement, a fourth author made the final decision.

Results: Within this review, 13 studies were examined, comprising 12 original articles and one systematic review. The findings were in favor of MPFL reconstruction, showing a significant reduction in the risk of recurrent instability, fewer additional surgeries, and a greater likelihood of resuming sports compared to conservative treatment. In terms of graft options for reconstruction, the gracilis tendon autograft is frequently used. However, allograft usage is gaining attention for its advantages in preserving native tissue and its superior mechanical properties, which are especially beneficial for patients with hyperlaxity. Fluoroscopy is instrumental in accurately locating the MPFL origin and avoiding growth plate damage. Therefore, optimal intraoperative imaging angles are critical.

Conclusions: The findings from this review suggest that MPFL reconstruction is an appropriate treatment option for recurrent patellar dislocation in skeletally immature patients, yielding significant improvements in patient-reported outcomes and demonstrating a markedly low rate of redislocation at follow-up. Nevertheless, further comprehensive, high-quality research is needed.

KEYWORDS: Ligament, Patellofemoral, Medial, Pediatrics.



This work is licensed under a [Creative Commons Attribution-NonCommercial-ShareAlike 4.0 International License](https://creativecommons.org/licenses/by-nc-sa/4.0/)

INTRODUCTION

The medial patellofemoral ligament (MPFL) is crucial for maintaining knee stability by preventing the patella from moving excessively or dislocating¹. Patellofemoral instability can lead to significant pain, arthritis, and functional limitations. MPFL reconstruction is commonly used to correct patellar instability and prevent recurrent dislocations^{1,2}.

Patellofemoral instability typically manifests in pediatric patients between 10 and 16 years of age, although specific populations such as children with neuromuscular disorders or joint hyperlaxity may show symptoms earlier². This condition calls for surgical intervention, particularly after recurrent dislocations³⁻⁵.

The MPFL is the primary soft-tissue structure preventing lateral patellar displacement, making its reconstruction a go-to treatment for instability, particularly in children with still-developing bones³.

However, MPFL reconstruction in skeletally immature patients is technically demanding, mainly due to the proximity of the graft fixation point (Schöttle's point) to the distal femoral growth plate and due to the fact that the isometric point migrates from epiphyseal to physeal during growth^{4,5}. Therefore, isometric MPFL reconstruction in young patients involves specific fixation techniques to minimize the risk to the growth plate^{1,6-8}. Although several surgical techniques for MPFL reconstruction have been outlined^{9,10} a consensus regarding the optimal graft type or surgical technique for skeletally immature patients is lacking.

Since the MPFL is always damaged following lateral patellar dislocation, reconstruction aims to reduce the recurrence of such dislocations^{7,8}.

This review aims to assess the effectiveness of MPFL reconstruction in the pediatric population and ascertain whether the choice of graft and fixation technique influences the clinical outcome, focusing on the best timing of the surgical procedure and possible additional procedures (e.g., medial tuberosity transposition)^{2,11-13}.

MATERIALS AND METHODS

This review was conducted by searching various digital databases, including PubMed, Medline, EMBASE, and Google Scholar, for articles published up to October 2023. The search terms used were 'Medial Patellofemoral Ligament', 'MPFL', 'Reconstruction', 'Repair', 'Surgery', 'Technique', 'Pediatric', and 'Children', applied both individually and in combination to yield a wide range of relevant studies.

Studies were included if they discussed techniques and outcomes of MPFL surgery in the pediatric population. Exclusion criteria encompassed non-English language articles, articles that lacked specific data on MPFL surgery techniques and outcomes, or those not addressing MPFL surgery in pediatric patients.

Initially, 134 articles were identified. Following the automated removal of duplicates and non-English articles, 91 remained. Of these, 41 were excluded for not providing specific data on MPFL surgery techniques and outcomes, and 36 were excluded for not addressing MPFL surgery in the pediatric population, leaving 13 articles for inclusion in the review.

Three independent authors, one resident (AP) and two researchers (FU and FP), reviewed each article for inclusion. In cases of disagreement, a fourth author made the final decision. The data extracted included the author(s), publication year, study design, population, type of surgical intervention, factors analyzed, results, and key findings regarding MPFL surgery outcomes. This rigorous method aimed to provide a comprehensive and objective overview of the current state of the art in MPFL surgery (Figure 1).

RESULTS

Within this review, 13 studies were examined, comprising 12 original articles and one systematic review (Table 1).

Bangert et al¹ investigation into the Ali Krogius technique, which involved 33 knees, revealed a 24.2% rate of redislocation, predominantly in 16-year-old or younger patients. Revision was necessary for one knee (3%) due to ongoing pain. Median Kujala and Lysholm scores were 86 and 90, respectively, with a median Tegner score of 6. Clinically, 21% of knees displayed lateralized patellar glide, and 24% presented an apprehension sign.

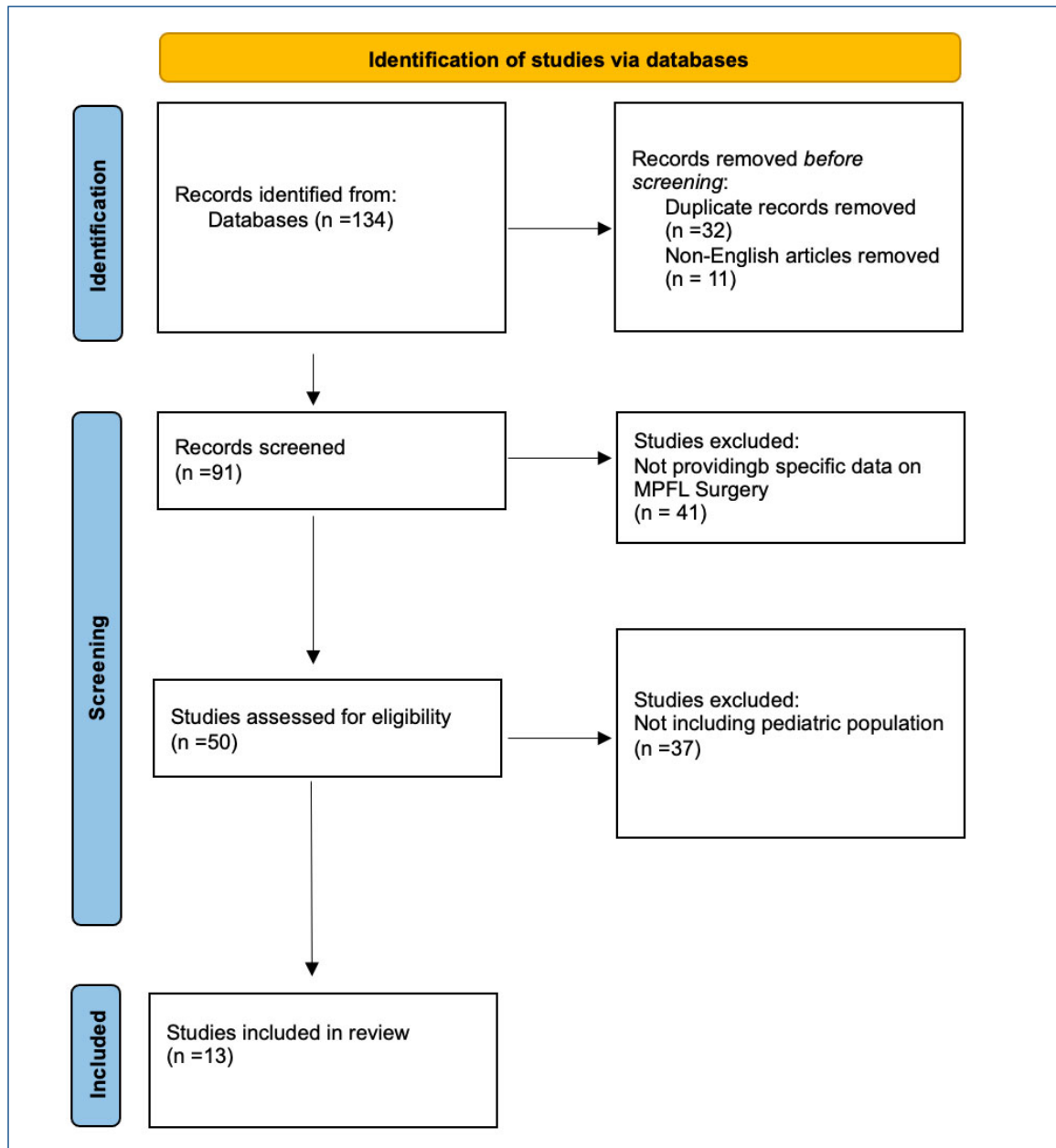


Figure 1. Flowchart of studies' identification *via* databases.

In the study by Knapik et al², it was observed that angling the drill at an average of $27 \pm 7^\circ$ from the joint line led to a significant breach of the intercondylar notch. The angle at which notch violation was most evident under fluoroscopy averaged $43 \pm 15^\circ$ (range: $10-60^\circ$) from the neutral position.

Featherall et al³ analyzed 49 pediatric knee CT scans, noting the average distance from the medial physis to the Schottle point was 9.9 ± 3.0 mm. They suggested that using a 6 mm reaming diameter could risk physeal injury in 6% of cases; however, adjusting the entry point by 3 mm distally eliminated this risk.

Gurusamy et al⁴ enrolled 76 patients and found that those undergoing MPFL reconstruction had a smaller Insall-Salvati ratio (1.29 vs. 1.42; $p=0.011$) and lower rates of recurrent instability and subsequent surgeries compared to those receiving repair or no treatment. There was also a higher likelihood of returning to sports, yet no significant difference in patient-reported outcomes.

Hendawi et al⁵ compared autograft vs. allograft gracilis tendon for MPFL reconstruction across 56 patients.

Table 1. Summary of patient characteristics, study outcomes, and complications.

Authors	Year of publication	Sample size	Average age	Technique	Graft	Clinical outcomes	Radiological outcomes	Complications
Bangert et al ¹	2022	33	20.8 yrs	Ali Krogus	Medial retinaculum	Median: 86% in the Kujala score 90% in the Lysholm score 88% in the IKDC 2000 93% in the KOOS score 6 in the Tegner score	N/A	Re-dislocation (24.2%)
Knapik et al ²	2022	14	Adult specimens	N/A	N/A	N/A	Fluoroscopic angle with higher notch violation: mean angle of 43±15° (range: 10-60 degrees) from neutral	N/A
Featherall et al ³	2022	49	13±2.3 yrs	N/A	N/A	N/A	In 49 of 49 cases (100%): the Schottle point distal to the physis on 3D volume rendering. The Schottle point mean distance: 7.5±3.14 mm posterior to medial epicondyle 6.2±2.9 mm superior to medial epicondyle	N/A
Gurusamy et al ⁴	2021	76	14±1.9 yrs	MPFL reconstruction, repair, or conservative treatment	N/A	SANE score: Conservative/repair 84.3 +/- 11.8 Reconstruction 88.7 +/- 10.1 <i>p</i> -value 0.134 Kujala: Conservative/repair 89.4 +/- 10.4 Reconstruction 92.7 +/- 7.6 <i>p</i> -value 0.276 Patient satisfaction (0-10): Conservative/repair 8.8 +/- 1.3 Reconstruction 9.4 6 +/- 0.9 <i>p</i> -value 0.08	N/A	Recurrent instability: conservative/repair group (59%) reconstruction group (10%) Second surgery: conservative/repair group (48%) reconstruction group (7%)

Continued

Table 1 (continued). Summary of patient characteristics, study outcomes, and complications.

Authors	Year of publication	Sample size	Average age	Technique	Graft	Clinical outcomes	Radiological outcomes	Complications
Hendawi et al ⁵	2019	Autograft group: 21 Allograft group: 35	Autograft group: 15.3 yrs Allograft group: 16 yrs	MPFL reconstruction: L-shaped tunnel at the proximal third of the patella with a 3.5-mm drill bit. On the femur, a guidewire was drilled from medial to lateral out the lateral thigh. A reamer was used to overdrill the guidewire	Gracilis tendon autograft or allograft	Autograft group: Kujala score: 80.3 Allograft group: Kujala score: 92.1	N/A	Autograft group: Graft failure (28.6%) Allograft group: Graft failure (0%)
Irrázaval et al ⁶	2020	80	10-17 yrs	N/A	N/A	N/A	Ideal orientation for femoral drilling during anatomic reconstruction of MPFL was obtained when aiming 30-40° distal and 5-35° anterior, regardless of sex	N/A
Masquijo et al ⁷	2021	20	Skeletally immature patients (average age not available)	N/A	N/A	N/A	Femoral graft fixation site 1 cm distal to the physis along the posterior femoral cor-tex in the lateral view closely represents the length relationship of the nMPFL	N/A
Pascual-Leone et al ⁸	2023	MPFLR + AMZ 28 iMPFLR 28	15.5±2 yrs	MPFLR+AMZ or iMPFLR	N/A	N/A	6.2° improvement in patellar tilt following MPFLR + AMZ and 3.9° improvement in patellar tilt following iMPFLR	N/A
Quinlan et al ⁹	2022	88 (67 skeletally mature (SM), 21 skeletally immature (SI))	Skeletally mature: 15.4 yrs Skeletally immature: 13.1 yrs	5-mm reamer used to drill the patellar tunnel. Graft trimmed to fit 5-mm tunnels and fixed into the tunnel using a 4.75-mm PEEK tenodesis interference screw	Semitendinosus allograft 35 SM 11 SI Gracilis allograft 25 SM 3 SI Peroneus longus allograft 1 SM 1 SI Tibialis anterior allograft 1 SM 0 SI Unspecified allograft 5 SM 2 SI	IKDC score, mean (SD) 77.8 (18.0) SM 77.3 (22.5) SI <i>p</i> -value 0.921 Marx Activity Scale score, mean (SD) 9.0 (4.8) SM 10.0 (5.3) SI <i>p</i> -value 0.487	N/A	Recurrent lateral patellar instability: SM 3% SI 9% Subsequent ipsilateral surgery for patellar instability: SM 10% SI 13% Stiffness: SM 43% SI 38%

Continued

Table 1 (continued). Summary of patient characteristics, study outcomes, and complications.

Authors	Year of publication	Sample size	Average age	Technique	Graft	Clinical outcomes	Radiological outcomes	Complications
Allahabadi and Pandya ¹⁰	2021	20	15.7 yrs	Double-bundle technique	Gracilis allograft	MPFL reconstruction using allograft tissue has good outcomes at midterm follow-up, few complications, and a low rate of recurrent instability	N/A	Recurrent instability events (12.5%), patellar fractures (4.2%), persistent laxity on examination, loss of knee motion/arthrofibrosis, symptomatic hardware (8.3%), and wound complications
Shamrock et al ¹¹	2019	126	13.2 yrs	Modes of femoral fixation: soft tissue pulley around the medial collateral ligament (MCL) (n=11) or the adductor magnus (n=24) tendon, suture anchors (n=51) and interference screw fixation (n=46). Methods of patellar fixation: blind bone tunnel with an interference screw (n=5), a single bone tunnel in which the graft was looped (n=45), suture anchor fixation (n=41), and no osseous fixation, with the quadriceps tendon reflected from its intact insertion on the patella (n=41)	Autografts: gracilis tendon (n=80; 60.6%), quadriceps tendon (n=41; 31.1%), semitendinosus tendon (n=11; 8.3%).	Pooled Kujala scores improved from 59.1 to 84.6 following MPFL reconstruction	N/A	Recurrent instability: 15.2% Knee pain: 3.8%
Uppstrom et al ¹²	2019	49	13.3±1.6 yrs	Short patellar and femoral sockets with tenodesis screws for fixation	Hamstrings autograft	N/A	Reconstructing the MPFL using femoral sockets for graft fixation: safe technique that does not lead to significant disturbances of the distal femoral physis	Recurrent patellar instability: 9.3% Subsequent patellar realignment with tibial tubercle osteotomy (TTO): 5.6%
Zampieri et al ¹³	2022	57	14 yrs	Tendon-tendon fixation (29) Anchor-screw fixation (28) 13 patients underwent ATT medialization or ATT medialization with lowering of patellar tendon or Grammont procedure	Gracilis autograft	Anchor-screw fixation reduces risk of patellar dislocation recurrence. Functional outcomes comparable with the two techniques	N/A	Tendon-tendon fixation: 2 dislocation recurrences, 2 stiffness, 1 removal of ATT screw Anchor-screw fixation: 1 disabling pain, 2 removal of ATT screw

iMPFLR: isolated medial patellofemoral ligament reconstruction. MPFLR + AMZ: medial patellofemoral ligament reconstruction + anterior medializing osteotomy. ATT: anterior tibial tuberosity. SM: skeletally mature. SI: skeletally immature. IKDC: The International Knee Documentation Committee. KOOS: Knee Injury and Osteoarthritis Outcome. SANE: Single Assessment Numeric Evaluation.

Numerous autograft options exist for MPFL reconstruction, including semitendinosus, gracilis, fascia lata, and quadriceps tendon¹³. The autograft group experienced longer surgeries, higher graft failure rates, and lower Kujala scores. Failures were exclusively in patients with chronic dislocations, and occurred at an average of 13.8 months post-surgery, suggesting higher costs due to reoperations for autografts.

Irrarazaval et al⁶ an innovative software software to model the distal femur and deep femoral physis, aiming to optimize MPFL insertion point drilling. The study found that the maximum physeal damage [5.35% (4.47-6.24)] was associated with the 7-mm drill when drilling 3° cephalic and 15° posterior from the insertion point, and this was consistent across genders (showing no statistically significant differences). Conversely, the minimum physeal damage [0.22% (0.07-0.37)] was observed with the 5-mm drill aimed at 45° distal and 0° anteroposterior, and this effect was not influenced by gender. For minimizing intra-articular drilling-related damage, the safest zone was identified when aiming between 30-40° distal and 5-35° anterior, irrespective of gender.

Masquijo et al⁷ study on twenty skeletally immature patients indicated significant differences in graft length when nonanatomic femoral points were used for MPFL insertion compared to the native MPFL. The most anatomically representative point was 1 cm distal to the physis along the posterior femoral cortex, demonstrating the closest length relationship to the native MPFL.

Pascual-Leone et al⁸ observed a notable improvement in patellar tilt in patients undergoing MPFL reconstruction with or without anterior medializing osteotomy. The combined procedure showed significantly less tilt postoperatively compared to reconstruction alone.

Quinlan et al⁹ reviewed patients under 18 who had primary allograft MPFL reconstruction, noting that skeletally immature patients had higher rates of ipsilateral injury and were less likely to opt for the same treatment if needed again despite no significant difference in redislocation rates.

Allahabadi and Pandya¹⁰ followed 20 patients who underwent MPFL reconstruction using allografts, noting no growth disturbances postoperatively and minimal complications, despite a small number of recurrent instabilities.

Shamrock et al¹¹ reported a 25% complication rate post-MPFL reconstruction, with no significant effect of autograft type or fixation method on recurrence or overall complications.

Uppstrom et al¹² found no significant differences in leg length or knee angle measurements post-surgery, with a low rate of recurrent instability. MRI exams post-surgery showed no signs of physeal arrest.

Zampieri et al¹³ determined that patients treated with tendon-tendon fixation had a higher dislocation rate compared to those with anchor-screw fixation. Yet, the overall clinical outcomes were comparable, with the tendon-tendon group having shorter tourniquet times but a higher complication rate.

DISCUSSION

The reconstruction of the medial patellofemoral ligament (MPFL) is a crucial procedure for addressing patellar instability in pediatric patients^{14,15}. This technique has shown^{16,17} considerable success, proving effective even in the presence of anatomical challenges such as trochlear dysplasia, joint hyperlaxity, and an increased TT-TG distance.

A current debate in the field revolves around the optimal treatment for acute MPFL injuries: whether to pursue conservative/repair methods or opt for reconstruction^{18,19}. Recent research, notably by Gurusamy et al⁴, compared outcomes of MPFL reconstruction with the repair or conservative treatment in pediatric and adolescent patients experiencing acute first-time patellar dislocations²⁰. The findings were in favor of reconstruction, showing a significant reduction in the risk of recurrent instability, fewer additional surgeries, and a greater likelihood of resuming sports^{4,20,21}. This study examines surgical interventions following first-time acute patellar dislocation. However, a review conducted by Lee et al²² found no significant disparities in clinical outcomes between conservative management and surgical intervention among children and adolescents experiencing acute patellar dislocation. Given the absence of substantial discrepancies in clinical outcomes between the two approaches, routine surgical intervention is not recommended for managing acute patellar dislocation in children and adolescents.

In terms of graft options for reconstruction, the gracilis tendon autograft is frequently used. However, allograft usage is gaining attention for its advantages in preserving native tissue and its superior mechanical properties, which are especially beneficial for patients with hyperlaxity. The trade-offs with allografts include higher costs and potential risks of disease transmission. Research by Hendawi et al⁵

showed that the gracilis allograft tendon offered increased survivorship and better Kujala scores compared to the autograft in pediatric populations^{5,22-24}.

For patients with open growth plates, various graft fixation techniques are employed, such as tendon-tendon and anchor-screw fixation²⁵. Studies²⁶ have yielded mixed results on the impact of these techniques on recurrent instability and overall clinical outcomes. Additionally, approaches like the Ali Krogus¹ technique (in which a strip of the medial retinaculum, pedicled proximally into the vastus medialis, is sewn into the lateral retinaculum), while protective of the epiphysis, have fallen out of favor due to high redislocation rates^{6,27,28}.

Fluoroscopy is instrumental in accurately locating the MPFL origin and avoiding growth plate damage. Optimal intraoperative imaging angles are critical^{9,29}, as recommended by Knapik et al².

Additionally, attention to tunnel diameter and implant length is crucial to prevent compromising the intercondylar notch^{3,30,31}.

The Schottle point³ serves as a reliable radiographic landmark, with consideration for reaming diameter and safe distance from the physis. It is necessary to always take into account the migration of the Schottle point from epiphyseal to physeal during growth^{2,32,33}.

Finally, recent studies^{2,12,34} have emphasized that MPFL reconstruction, including techniques that use all-epiphyseal femoral sockets for graft fixation, is a safe procedure that does not significantly disturb the distal femoral growth plate. This aspect is essential for maintaining normal growth in pediatric patients undergoing surgery.

When it comes to enhancing patellar alignment, MPFL reconstruction is often paired with anterior medializing osteotomy (AMZ)^{8,30}. The method is recommended for addressing symptomatic lateral instability of the patella, particularly when associated with an excessive Q angle, bony malalignment, or a combination of both factors, leading to an enlarged trochlea-tubercle distance²⁹. It is essential to note that the Elmslie-Trillat procedure is not suitable for application in skeletally immature knees or knees with preexisting conditions such as medial patellar subluxation, medial compartment arthrosis, or varus deformity^{8,29}. Studies, like the one by Pascual-Leone et al⁸, have shown that combining these procedures results in significant improvements in patellar tilt, with a greater enhancement observed in the combined approach²⁹⁻³¹.

Sappey-Marinier et al¹⁴ examined the clinical outcomes associated with isolated medial patellofemoral ligament (MPFL) reconstruction procedure in cases of lateral patellar instability. In cases of recurring patellar instability, an isolated MPFL reconstruction demonstrated a minimal failure rate. Additionally, this study identified preoperative risk factors for failure, including patella alta with a CDI ≥ 1.3 and a positive J-sign before surgery.

Graft selection is a crucial step preceding MPFL reconstruction. Given that the native MPFL exhibits a failure load of approximately 200 N, the ideal graft should possess similar biomechanical characteristics. Among the most popular options are autografts, including the gracilis, semitendinosus, and quadriceps tendon. It was documented³³⁻³⁵ that the maximum failure load for the gracilis, semitendinosus, and quadriceps tendon was 838 N, 1216 N, and 266 N, respectively. Each of these options offers higher failure loads compared to the native MPFL and, consequently, is deemed suitable for reconstruction. The quadriceps tendon was anyway found to have higher donor-site morbidity.

Contemporary literature^{34,35} indicates that the choice of graft does not significantly impact the outcomes of MPFL reconstruction; rather, it is typically based on surgeon's preference and experience.

In summary, MPFL reconstruction, while requiring meticulous attention to technical details, offers a safe and effective solution for treating patellar instability in children and adolescents, with a focus on preserving the growth plate to avoid complications^{36,37}. According to the findings of this review, authors suggest the use of an adductor sling technique with an autologous semitendinous or gracilis graft, which is a technique with minor damage in the pediatric population and can serve as a bridge surgery to possible further interventions when skeletal maturity is achieved.

Limitations

The present study has several limitations and potential biases. Firstly, there are different study types and designs, which leads to a greater risk of bias. Secondly, the numerous clinical and radiological scores used in these studies may lead to an incorrect and incomplete comparison of the results. Furthermore, the small sample size of patients included in the review does not allow researchers to reach well-grounded conclusions and reflects the need for studies on a larger population.

CONCLUSIONS

The findings from this literature review suggest that MPFL reconstruction is an appropriate treatment option for recurrent patellar dislocation in skeletally immature patients, yielding significant improvements in patient-reported outcomes and demonstrating a markedly low rate of redislocation at follow-up. Further comprehensive, high-quality research is needed to determine the optimal graft choices and to refine surgical techniques. Future studies should carefully balance considerations of stability, donor site morbidity, and the potential risk of damaging adjacent growth plates.

FUNDING:

No funding was received.

AUTHORS' CONTRIBUTIONS:

Francesco Uboldi, Paolo Ferrua, and Antonio Memeo gave substantial contributions to the design of the manuscript, while Arianna Pieroni, Daniele Priano, and Francesco Puglia contributed to the acquisition, analysis, and interpretation of the data. All authors participated in drafting the manuscript, and Francesco Puglia revised it critically. All authors read and approved the final version of the manuscript.

ORCID ID:

Francesco Uboldi: 0000-0002-3199-3899
Arianna Pieroni: 0000-0002-2772-0206
Francesco Puglia: 0000-0002-4886-4233
Paolo Ferrua: 0000-0002-7459-6762
Daniele Priano: 0000-0002-5123-4478
Antonio Memeo: 0000-0002-9715-6989

CONFLICT OF INTEREST:

The authors have no conflict of interest to disclose.

INFORMED CONSENT:

Not applicable.

ETHICS APPROVAL:

Not applicable.

REFERENCES

1. Bangert Y, Mittelstrass F, Weissborn J, Hagmann S, Barié A, Jaber A. The Ali Kroggius procedure for treatment of patellofemoral instability should be regarded as obsolete even in skeletally immature patients. *BMC Musculoskelet Disord* 2022; 23: 257.
2. Knapik DM, McCarthy CF, Drummond I, Liu RW, Gilmore A. Optimal Fluoroscopic Angulation to Determine Intercondylar Notch Violation during Pediatric Medial Patellofemoral Ligament Reconstruction. *J Knee Surg* 2022; 35: 1440-1444.
3. Featherall J, Metz AK, Froerer DL, Rosenthal RM, Mortensen AJ, Ernat JJ, Maak TG, Aoki SK. The Schöttle Point Is Consistently Located Distal to the Medial Femoral Physis in Pediatric Patients: A Digitally Reconstructed Radiographic Study. *Am J Sports Med* 2022; 50: 3565-3570.
4. Gurusamy P, Pedowitz JM, Carroll AN, Johnson K, Chambers HG, Edmonds EW, Pennock AT. Medial Patellofemoral Ligament Reconstruction for Adolescents With Acute First-Time Patellar Dislocation With an Associated Loose Body. *Am J Sports Med* 2021; 49: 2159-2164.
5. Hendawi T, Godshaw B, Flowers C, Stephens I, Haber L, Waldron S. Autograft vs Allograft Comparison in Pediatric Medial Patellofemoral Ligament Reconstruction. *Ochsner J* 2019; 19: 96-101.
6. Irrarrázaval S, Besa P, Fernández F, Fernández T, Tuca M, Lira MJ, Orrego M. Anterior and distal tunnel orientation for anatomic reconstruction of the medial patellofemoral ligament is safer in patients with open growth plates. *Knee Surg Sports Traumatol Arthrosc* 2021; 29: 1822-1829.
7. Masquijo J, Parikh SN, Kothari A. Evaluation of the Optimal Femoral Fixation Site for Medial Patellofemoral Ligament Reconstruction in the Skeletally Immature Patient. *Orthopedics* 2023; 46: 108-113.
8. Pascual-Leone N, Chipman DE, Meza BC, Mintz DN, Fabricant PD, Green DW. Concomitant anterior medializing osteotomy and MPFL reconstruction improves patellar tilt when compared to MPFL reconstruction alone. *Knee Surg Sports Traumatol Arthrosc* 2023; 31: 3399-3404.
9. Quinlan NJ, Tomasevich KM, Mortensen AJ, Hobson TE, Adeyemi T, Metz AK, Aoki SK. Medial Patellofemoral Ligament Reconstruction in the Pediatric Population: Skeletal Immaturity Does Not Affect Functional Outcomes but Demonstrates Increased Rate of Subsequent Knee Injury. *Arthrosc Sports Med Rehabil* 2022; 4: 1589-1599.

10. Allahabadi S, Pandya NK. Allograft Medial Patellofemoral Ligament Reconstruction in Adolescent Patients Results in a Low Recurrence Rate of Patellar Dislocation or Subluxation at Midterm Follow-Up. *Arthroscopy* 2022; 38: 128-138.
11. Shamrock AG, Day MA, Duchman KR, Glass N, Westermann RW. Medial Patellofemoral Ligament Reconstruction in Skeletally Immature Patients: A Systematic Review and Meta-analysis. *Orthop J Sports Med* 2019; 7: 2325967119855023.
12. Uppstrom TJ, Price M, Black S, Gausden E, Haskel J, Green DW. Medial patellofemoral ligament (MPFL) reconstruction technique using an epiphyseal femoral socket with fluoroscopic guidance helps avoid physeal injury in skeletally immature patients. *Knee Surg Sports Traumatol Arthrosc* 2019; 27: 3536-3542.
13. Zampieri A, Girardin C, Hocquet B, Coursier R, Fournier A, Martin C, Nectoux E, Canavese F. Patellar dislocation recurrence after pediatric MPFL reconstruction: Bone tunnels and soft tissues versus suture anchors and interference screw. *Orthop Traumatol Surg Res* 2023; 109: 103515.
14. Sappey-Mariniere E, Sonnery-Cottet B, O'Loughlin P, Ouanezar H, Reina Fernandes L, Kouevidjin B, Thauant M. Clinical Outcomes and Predictive Factors for Failure With Isolated MPFL Reconstruction for Recurrent Patellar Instability: A Series of 211 Reconstructions With a Minimum Follow-up of 3 Years. *Am J Sports Med* 2019; 47: 1323-1330.
15. Schlichte LM, Sidharthan S, Green DW, Parikh SN. Pediatric Management of Recurrent Patellar Instability. *Sports Med Arthrosc Rev* 2019; 27: 171-180.
16. McMellen CJ, Ina JG, Ren BO, Hanna P, Gilmore A. Modified Grammont Soft-Tissue Distal Patellar Realignment and Medial Patellofemoral Ligament Reconstruction for Patellofemoral Instability in Pediatric Patients. *Arthrosc Tech* 2022; 11: 2255-2263.
17. Malecki K, Niedzielski K, Flont P, Fabis-Strobin A, Fabis J. Bilateral Hidden Isokinetic Quadriceps Performance before and after MPFL Reconstruction in Pediatric Patients. *J Knee Surg* 2021; 34: 906-912.
18. Cannamela PC, Maak TG, Adeyemi TF, Aoki SK. Traumatic Pediatric Quadriceps Rupture After Medial Patellofemoral Ligament Reconstruction: A Case Report. *JBJS Case Connect* 2019; 9.
19. Parikh SN, Veerkamp M, Redler LH, Schlechter J, Williams BA, Yaniv M, Friel N, Perea SH, Shannon SR, Green DW. Patellar Instability in Young Athletes. *Clin Sports Med* 2022; 41: 627-651.
20. Jabbouri SS, McLaughlin W, Joo P, Cooperman D, Fulkerson JP, Frumberg DB. Localization of the Adductor Tubercle in the Skeletally Immature: A Computed Tomography Study With Patellofemoral Surgical Implications. *Am J Sports Med* 2023; 51: 1792-1798.
21. Decante C, Geffroy L, Salaud C, Chalopin A, Ploteau S, Hamel A. Descriptive and dynamic study of the medial patellofemoral ligament (MPFL). *Surg Radiol Anat* 2019; 41: 763-774.
22. Lee DY, Kang DG, Jo HS, Heo SJ, Bae JH, Hwang SC. A systematic review and meta-analysis comparing conservative and surgical treatments for acute patellar dislocation in children and adolescents. *Knee Surg Relat Res* 2023; 35: 18.
23. Gamble JG, Shirodkar RN, Gamble JG. Knee valgus and patellofemoral instability after pediatric anterior cruciate ligament reconstruction: a case report and review of the literature. *J Med Case Rep* 2023; 17: 212.
24. Sherman SL, Curtis DM. Editorial Commentary: Is the Pendulum "Swinging" Away From Patellar Fixation in Medial Patellofemoral Ligament Reconstruction? *Arthroscopy* 2021; 37: 3198-3199.
25. Matuszewski Ł, Tramś M, Ciszewski A, Wilczyński M, Tramś E, Jakubowski P, Matuszewska A, John K. Medial patellofemoral ligament reconstruction in children: A comparative randomized short-term study of fascia lata allograft and gracilis tendon autograft reconstruction. *Medicine (Baltimore)* 2018; 97: e13605.
26. Baskar D, Stavinoha TJ, Sanchez M, Gupta A, Randhawa SD, Rohde MS, Vuong B, Tompkins MA, Ganley TJ, Ellis HB Jr, Wilson PL, Fabricant PD, VandenBerg C, Green DW, Segovia NA, Shea KG. Quantifying the Relationship Between the Medial Quadriceps Tendon-Femoral Ligament and Patellar Borders: A Pediatric Cadaveric Study. *Am J Sports Med* 2022; 50: 2433-2438.
27. Roger J, Viste A, Cieviet-Bonfils M, Pracros JP, Raux S, Chotel F. Axial patellar engagement index and patellar tilt after medial patello-femoral ligament reconstruction in children and adolescents. *Orthop Traumatol Surg Res* 2019; 105: 133-138.
28. Elias JJ, Jones KC, Lalonde MK, Gabra JN, Rezvanifar SC, Cosgarea AJ. Allowing one quadrant of patellar lateral translation during medial patellofemoral ligament reconstruction successfully limits maltracking without overconstraining the patella. *Knee Surg Sports Traumatol Arthrosc* 2018; 26: 2883-2890.
29. Kay J, Memon M, Shah A, Yen YM, Samuelsson K, Peterson D, Simunovic N, Flageole H, Ayeni OR. Earlier anterior cruciate ligament reconstruction is associated with a decreased risk of medial meniscal and articular cartilage damage in children and adolescents: a systematic review and meta-analysis. *Knee Surg Sports Traumatol Arthrosc* 2018; 26: 3738-3753.
30. Gao B, Dwivedi S, Fabricant PD, Cruz AI Jr. Patterns in Outcomes Reporting of Operatively Managed Pediatric Patellofemoral Instability: A Systematic Review and Meta-analysis. *Am J Sports Med* 2019; 47: 1516-1524.
31. Pedowitz JM, Edmonds EW, Chambers HG, Dennis MM, Bastrom T, Pennock AT. Recurrence of Patellar Instability in Adolescents Undergoing Surgery for Osteochondral Defects Without Concomitant Ligament Reconstruction. *Am J Sports Med* 2019; 47: 66-70.
32. Bryant J, Pandya N. Medial patellofemoral ligament repair restores stability in pediatric patients when compared to reconstruction. *Knee* 2018; 25: 602-608.
33. Halpern L, Kogan CJ, Arnzen G. Peripheral Nerve Blockade for Medial Patellofemoral Ligament Reconstruction in Pediatric Patients: The Addition of a Proximal Single-Injection Sciatic Nerve Block Provides Improved Analgesia. *Local Reg Anesth* 2022; 15: 31-43.
34. Hohn E, Pandya NK. Does the Utilization of Allograft Tissue in Medial Patellofemoral Ligament Reconstruction in Pediatric and Adolescent Patients Restore Patellar Stability? *Clin Orthop Relat Res* 2017; 475: 1563-1569.
35. Ferrua P, Kruckeberg BM, Pasqualotto S, Berruto M, Randelli P, Arendt EA. Proximal medial patellar restraints and their surgical reconstruction. *J Orthop Traumatol* 2019; 20: 17.
36. Nguyen CV, Farrow LD, Liu RW, Gilmore A. Safe Drilling Paths in the Distal Femoral Epiphysis for Pediatric Medial Patellofemoral Ligament Reconstruction. *Am J Sports Med* 2017; 45: 1085-1089.
37. Fabricant PD. CORR Insights: Does the Utilization of Allograft Tissue in Medial Patellofemoral Ligament Reconstruction in Pediatric and Adolescent Patients Restore Patellar Stability? *Clin Orthop Relat Res* 2017; 475: 1570-1572.